

## Diagnosis and Management of Cerebral Venous Thrombosis A Statement for Healthcare Professionals From the American Heart Association/American Stroke Association

*The American Academy of Neurology affirms the value of this statement as an educational tool for neurologists.*

*The American Association of Neurological Surgeons and Congress of Neurological Surgeons have reviewed this document and affirm its educational content.*

*The Ibero-American Stroke Society (Sociedad Iberoamericana de Enfermedad Cerebrovascular) endorses the recommendations contained in this report.*

*Endorsed by the Society of NeuroInterventional Surgery*

Gustavo Saposnik, MD, MSc, FAHA, Chair; Fernando Barinagarrementeria, MD, FAHA, FAAN; Robert D. Brown, Jr, MD, MPH, FAHA, FAAN; Cheryl D. Bushnell, MD, MHS, FAHA; Brett Cucchiara, MD, FAHA; Mary Cushman, MD, MSc, FAHA; Gabrielle deVeber, MD; Jose M. Ferro, MD, PhD; Fong Y. Tsai, MD; on behalf of the American Heart Association Stroke Council and the Council on Epidemiology and Prevention

**Background**—The purpose of this statement is to provide an overview of cerebral venous sinus thrombosis and to provide recommendations for its diagnosis, management, and treatment. The intended audience is physicians and other healthcare providers who are responsible for the diagnosis and management of patients with cerebral venous sinus thrombosis.

**Methods and Results**—Members of the panel were appointed by the American Heart Association Stroke Council's Scientific Statement Oversight Committee and represent different areas of expertise. The panel reviewed the relevant literature with an emphasis on reports published since 1966 and used the American Heart Association levels-of-evidence grading algorithm to rate the evidence and to make recommendations. After approval of the statement by the panel, it underwent peer review and approval by the American Heart Association Science Advisory and Coordinating Committee.

**Conclusions**—Evidence-based recommendations are provided for the diagnosis, management, and prevention of recurrence of cerebral venous thrombosis. Recommendations on the evaluation and management of cerebral venous thrombosis during pregnancy and in the pediatric population are provided. Considerations for the management of clinical complications (seizures, hydrocephalus, intracranial hypertension, and neurological deterioration) are also summarized. An algorithm for diagnosis and management of patients with cerebral venous sinus thrombosis is described. (*Stroke*. 2011;42:1158-1192.)

**Key Words:** AHA Scientific Statements ■ venous thrombosis ■ sinus thrombosis, intracranial

■ brain infarction, venous ■ stroke ■ disease management ■ prognosis ■ outcome assessment ■ anticoagulants  
■ pregnancy ■ children

---

Author order is alphabetical after the writing group chair. All authors have contributed equally to the present work.

The American Heart Association makes every effort to avoid any actual or potential conflicts of interest that may arise as a result of an outside relationship or a personal, professional, or business interest of a member of the writing panel. Specifically, all members of the writing group are required to complete and submit a Disclosure Questionnaire showing all such relationships that might be perceived as real or potential conflicts of interest.

This statement was approved by the American Heart Association Science Advisory and Coordinating Committee on October 26, 2010. A copy of the statement is available at <http://www.americanheart.org/presenter.jhtml?identifier=3003999> by selecting either the "topic list" link or the "chronological list" link (No. KB-0186). To purchase additional reprints, call 843-216-2533 or e-mail [kelle.ramsay@wolterskluwer.com](mailto:kelle.ramsay@wolterskluwer.com).

The American Heart Association requests that this document be cited as follows: Saposnik G, Barinagarrementeria F, Brown RD Jr, Bushnell CD, Cucchiara B, Cushman M, deVeber G, Ferro JM, Tsai FY; on behalf of the American Heart Association Stroke Council and the Council on Epidemiology and Prevention. Diagnosis and management of cerebral venous thrombosis: a statement for healthcare professionals from the American Heart Association/American Stroke Association. *Stroke*. 2011;42:1158-1192.

Expert peer review of AHA Scientific Statements is conducted at the AHA National Center. For more on AHA statements and guidelines development, visit <http://www.americanheart.org/presenter.jhtml?identifier=3023366>.

Permissions: Multiple copies, modification, alteration, enhancement, and/or distribution of this document are not permitted without the express permission of the American Heart Association. Instructions for obtaining permission are located at <http://www.americanheart.org/presenter.jhtml?identifier=4431>. A link to the "Permission Request Form" appears on the right side of the page.

© 2011 American Heart Association, Inc.

*Stroke* is available at <http://stroke.ahajournals.org>

DOI: 10.1161/STR.0b013e31820a8364

**T**hrombosis of the dural sinus and/or cerebral veins (CVT) is an uncommon form of stroke, usually affecting young individuals.<sup>1</sup> Despite advances in the recognition of CVT in recent years, diagnosis and management can be difficult because of the diversity of underlying risk factors and the absence of a uniform treatment approach. CVT represents  $\approx 0.5\%$  to  $1\%$  of all strokes.<sup>2</sup> Multiple factors have been associated with CVT, but only some of them are reversible. Prior medical conditions (eg, thrombophilias, inflammatory bowel disease), transient situations (eg, pregnancy, dehydration, infection), selected medications (eg, oral contraceptives, substance abuse), and unpredictable events (eg, head trauma) are some predisposing conditions.<sup>3,4</sup>

Given the diversity of causes and presenting scenarios, CVT may commonly be encountered not only by neurologists and neurosurgeons but also by emergency physicians, internists, oncologists, hematologists, obstetricians, pediatricians, and family practitioners. Our purpose in the present scientific statement is to review the literature on CVT and to provide recommendations for its diagnosis and management. Writing group members were appointed by the American Heart Association (AHA) Stroke Council's Scientific Statement Oversight Committee and the Council on Epidemiology and Prevention. The panel included members with several different areas of expertise. The panel reviewed relevant articles on CVT in adults and children using computerized searches of the medical literature through July 2010. These articles were supplemented by other articles known to the authors. The evidence is organized within the context of the AHA framework and is classified according to the joint AHA/American College of Cardiology Foundation and supplementary AHA Stroke Council methods of classifying the level of certainty and the class and level of evidence (Tables 1 and 2).<sup>5</sup> After review by the panel members, the manuscript was reviewed by expert peer reviewers and members of the Stroke Council Leadership Committee and was subsequently approved by the AHA's Science Advisory and Coordinating Committee.

Although information about the cause and clinical manifestations of CVT is included for the convenience of readers who may be unfamiliar with these topics, the group's recommendations emphasize issues regarding diagnosis, management, and treatment. The recommendations are based on the current available evidence and were approved by all members of the writing group. Despite major progress in the evaluation and management of this rare condition in recent years, much of the literature remains descriptive. In some areas, evidence is lacking to guide decision making; however, the writing group made an effort to highlight those areas and provide suggestions, with the understanding that some physicians may need more guidance, particularly in making decisions when extensive evidence is not available. Continued research is essential to better understand issues related to the diagnosis and treatment of CVT. Identification of subgroups at higher risk would allow a more careful selection of patients who may benefit from selective interventions or therapies.

### **Epidemiology and Risk Factors for CVT**

CVT is an uncommon and frequently unrecognized type of stroke that affects approximately 5 people per million annu-

ally and accounts for 0.5% to 1% of all strokes.<sup>1</sup> CVT is more commonly seen in young individuals. According to the largest cohort study (the International Study on Cerebral Venous and Dural Sinuses Thrombosis [ISCVT]), 487 (78%) of 624 cases occurred in patients  $<50$  years of age (Figure 1).<sup>6</sup> Clinical features are diverse, and for this reason, cases should be sought among diverse clinical index conditions. A prior pathological study found a prevalence of CVT of 9.3% among 182 consecutive autopsies.<sup>7</sup> No population studies have reported the incidence of CVT. Very few stroke registries included cases with CVT. This may result in an overestimation of risk associated with the various conditions owing to referral and ascertainment biases. In the Registro Nacional Mexicano de Enfermedad Vasculares Cerebrales (RENAMEVASC), a multihospital prospective Mexican stroke registry, 3% of all stroke cases were CVT.<sup>8</sup> A clinic-based registry in Iran reported an annual CVT incidence of 12.3 per million.<sup>9</sup> In a series of intracerebral hemorrhage (ICH) cases in young people, CVT explained 5% of all cases.<sup>9</sup>

### **Cause and Pathogenesis: Underlying Risk Factors for CVT**

Predisposing causes of CVT are multiple. The risk factors for venous thrombosis in general are linked classically to the Virchow triad of stasis of the blood, changes in the vessel wall, and changes in the composition of the blood. Risk factors are usually divided into acquired risks (eg, surgery, trauma, pregnancy, puerperium, antiphospholipid syndrome, cancer, exogenous hormones) and genetic risks (inherited thrombophilia).

Table 3 summarizes the evidence for a cause-and-effect relationship<sup>10,11</sup> between prothrombotic factors and CVT.<sup>12–55</sup> Evidence for the strength and consistency of association, biological plausibility, and temporality is summarized. These criteria are most closely met for deficiency of antithrombin III, protein C, and protein S; factor V Leiden positivity; use of oral contraceptives; and hyperhomocysteinemia, among others.

### **Prothrombotic Conditions**

The most widely studied risk factors for CVT include prothrombotic conditions. The largest study, the ISCVT, is a multinational, multicenter, prospective observational study with 624 patients. Thirty-four percent of these patients had an inherited or acquired prothrombotic condition.<sup>10</sup> The prevalence of different prothrombotic conditions is summarized in Table 3. Recently, another group in the United States reported that 21% of 182 CVT case subjects in 10 hospitals had a prothrombotic condition.<sup>11</sup>

### **Antithrombin III, Protein C, and Protein S Deficiency**

Two studies have analyzed the role of natural anticoagulant protein deficiencies (antithrombin III, protein C, and protein S) as risk factors for CVT. One study compared 121 patients with a first CVT with 242 healthy control subjects.<sup>36</sup> The other study compared 51 patients with CVT with 120 healthy control subjects.<sup>12</sup> Only 1 patient (2%) had antithrombin III deficiency. The combined odds ratio (OR) of CVT when these 2 studies were combined was 11.1 for protein C deficiency (95% confi-

Table 1. Applying Classification of Recommendations and Level of Evidence

		SIZE OF TREATMENT EFFECT <span style="float: right;">➔</span>			
		CLASS I <i>Benefit &gt;&gt;&gt; Risk</i> Procedure/Treatment <b>SHOULD</b> be performed/administered	CLASS IIa <i>Benefit &gt;&gt; Risk</i> <i>Additional studies with focused objectives needed</i> <b>IT IS REASONABLE</b> to perform procedure/administer treatment	CLASS IIb <i>Benefit ≥ Risk</i> <i>Additional studies with broad objectives needed; additional registry data would be helpful</i> Procedure/Treatment <b>MAY BE CONSIDERED</b>	CLASS III <i>Risk ≥ Benefit</i> Procedure/Treatment should <b>NOT</b> be performed/administered <b>SINCE IT IS NOT HELPFUL AND MAY BE HARMFUL</b>
ESTIMATE OF CERTAINTY (PRECISION) OF TREATMENT EFFECT	LEVEL A Multiple populations evaluated* Data derived from multiple randomized clinical trials or meta-analyses	<ul style="list-style-type: none"> <li>■ Recommendation that procedure or treatment is useful/effective</li> <li>■ Sufficient evidence from multiple randomized trials or meta-analyses</li> </ul>	<ul style="list-style-type: none"> <li>■ Recommendation in favor of treatment or procedure being useful/effective</li> <li>■ Some conflicting evidence from multiple randomized trials or meta-analyses</li> </ul>	<ul style="list-style-type: none"> <li>■ Recommendation's usefulness/efficacy less well established</li> <li>■ Greater conflicting evidence from multiple randomized trials or meta-analyses</li> </ul>	<ul style="list-style-type: none"> <li>■ Recommendation that procedure or treatment is not useful/effective and may be harmful</li> <li>■ Sufficient evidence from multiple randomized trials or meta-analyses</li> </ul>
	LEVEL B Limited populations evaluated* Data derived from a single randomized trial or nonrandomized studies	<ul style="list-style-type: none"> <li>■ Recommendation that procedure or treatment is useful/effective</li> <li>■ Evidence from single randomized trial or nonrandomized studies</li> </ul>	<ul style="list-style-type: none"> <li>■ Recommendation in favor of treatment or procedure being useful/effective</li> <li>■ Some conflicting evidence from single randomized trial or nonrandomized studies</li> </ul>	<ul style="list-style-type: none"> <li>■ Recommendation's usefulness/efficacy less well established</li> <li>■ Greater conflicting evidence from single randomized trial or nonrandomized studies</li> </ul>	<ul style="list-style-type: none"> <li>■ Recommendation that procedure or treatment is not useful/effective and may be harmful</li> <li>■ Evidence from single randomized trial or nonrandomized studies</li> </ul>
	LEVEL C Very limited populations evaluated* Only consensus opinion of experts, case studies, or standard of care	<ul style="list-style-type: none"> <li>■ Recommendation that procedure or treatment is useful/effective</li> <li>■ Only expert opinion, case studies, or standard of care</li> </ul>	<ul style="list-style-type: none"> <li>■ Recommendation in favor of treatment or procedure being useful/effective</li> <li>■ Only diverging expert opinion, case studies, or standard of care</li> </ul>	<ul style="list-style-type: none"> <li>■ Recommendation's usefulness/efficacy less well established</li> <li>■ Only diverging expert opinion, case studies, or standard of care</li> </ul>	<ul style="list-style-type: none"> <li>■ Recommendation that procedure or treatment is not useful/effective and may be harmful</li> <li>■ Only expert opinion, case studies, or standard of care</li> </ul>
Suggested phrases for writing recommendations†		should is recommended is indicated is useful/effective/beneficial	is reasonable can be useful/effective/beneficial is probably recommended or indicated	may/might be considered may/might be reasonable usefulness/effectiveness is unknown/unclear/uncertain or not well established	is not recommended is not indicated should not is not useful/effective/beneficial may be harmful

\*Data available from clinical trials or registries about the usefulness/efficacy in different subpopulations, such as gender, age, history of diabetes, history of prior myocardial infarction, history of heart failure, and prior aspirin use. A recommendation with Level of Evidence B or C does not imply that the recommendation is weak. Many important clinical questions addressed in the guidelines do not lend themselves to clinical trials. Even though randomized trials are not available, there may be a very clear clinical consensus that a particular test or therapy is useful or effective.

†For recommendations (Class I and IIa; Level of Evidence A and B only) regarding the comparative effectiveness of one treatment with respect to another, these words or phrases may be accompanied by the additional terms "in preference to" or "to choose" to indicate the favored intervention. For example, "Treatment A is recommended in preference to Treatment B for..." or "It is reasonable to choose Treatment A over Treatment B for..." Studies that support the use of comparator verbs should involve direct comparisons of the treatments or strategies being evaluated.

dence interval [CI] 1.87 to 66.05;  $P=0.009$ ) and 12.5 for protein S deficiency (95% CI 1.45 to 107.29;  $P=0.03$ ).

### Antiphospholipid and Anticardiolipin Antibodies

The first study mentioned above found a higher prevalence of antiphospholipid antibodies in patients with CVT (9 of 121) than in control subjects (0 of 242).<sup>36</sup> In another study from India with 31 CVT patients, anticardiolipin antibodies were detected in 22.6% of CVT patients compared with 3.2% of normal control subjects.<sup>12</sup> Similar findings (5.9%) were observed in the ISCVT study.<sup>10</sup>

### Factor V Leiden Gene Mutation and Resistance to Activated Protein C

Resistance to activated protein C is mainly caused by the presence of the factor V Leiden gene mutation, which is a common inherited thrombophilic disorder. A recent meta-anal-

ysis of 13 studies, including 469 CVT cases and 3023 control subjects,<sup>28</sup> reported a pooled OR of CVT of 3.38 (95% CI 2.27 to 5.05) for factor V Leiden, which is similar to its association with venous thromboembolism (VTE) in general.<sup>28</sup>

### Prothrombin G20210A Mutation

The prothrombin G20210A mutation is present in ≈2% of whites and causes a slight elevation of prothrombin level.<sup>55,56</sup> A meta-analysis of 9 studies,<sup>38</sup> including 360 CVT patients and 2688 control subjects, reported a pooled OR of CVT of 9.27 (95% CI 5.85 to 14.67) for this mutation,<sup>28</sup> which is stronger than its association with VTE in general.

### Hyperhomocysteinemia

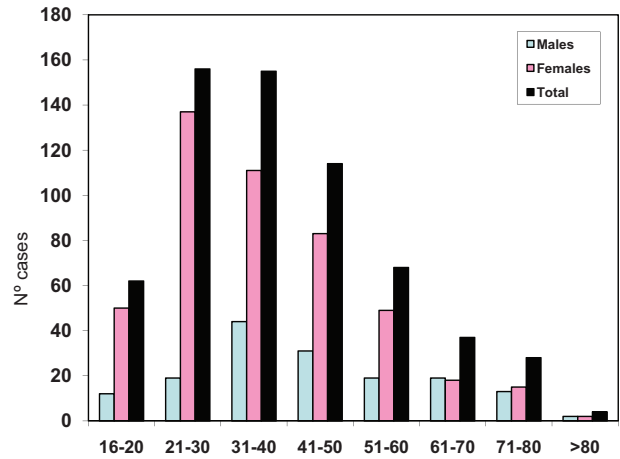
Hyperhomocysteinemia is a risk factor for deep vein thrombosis (DVT) and stroke but has not been clearly associated with an increased risk of CVT. Five case-control studies evaluated

**Table 2. Definition of Classes and Levels of Evidence Used in AHA Stroke Council Recommendations**

Class I	Conditions for which there is evidence for and/or general agreement that the procedure or treatment is useful and effective.
Class II	Conditions for which there is conflicting evidence and/or a divergence of opinion about the usefulness/efficacy of a procedure or treatment.
Class IIa	The weight of evidence or opinion is in favor of the procedure or treatment.
Class IIb	Usefulness/efficacy is less well established by evidence or opinion.
Class III	Conditions for which there is evidence and/or general agreement that the procedure or treatment is not useful/effective and in some cases may be harmful.
Therapeutic recommendations	
Level of Evidence A	Data derived from multiple randomized clinical trials or meta-analyses
Level of Evidence B	Data derived from a single randomized trial or nonrandomized studies
Level of Evidence C	Consensus opinion of experts, case studies, or standard of care
Diagnostic recommendations	
Level of Evidence A	Data derived from multiple prospective cohort studies using a reference standard applied by a masked evaluator
Level of Evidence B	Data derived from a single grade A study, or ≥1 case-control studies, or studies using a reference standard applied by an unmasked evaluator
Level of Evidence C	Consensus opinion of experts

hyperhomocysteinemia in patients with CVT.<sup>13,16,17,29,30</sup> Researchers from Milan<sup>13</sup> reported on 121 patients with a first CVT and 242 control subjects, finding hyperhomocysteinemia in 33 patients (27%) and 20 control subjects (8%; OR 4.2, 95% CI 2.3 to 7.6). Low levels of serum folate and the 677TT methylenetetrahydrofolate reductase genotype were not associated with CVT risk, independent of homocysteine level.<sup>13</sup>

A study of 45 patients with CVT and 90 control subjects in Mexico reported an adjusted OR of CVT of 4.6 (95% CI 1.6 to 12.8) associated with high fasting homocysteine and an OR of 3.5 (95% CI 1.2 to 10.0) associated with low folate.<sup>29</sup> A small Italian study of 26 consecutive patients with CVT and 100 healthy control subjects reported that 38.5% of case subjects and 13% of control subjects had hyperhomocysteinemia (OR 4.2, 95% CI 1.6 to 11.2).<sup>16</sup> No significant differences were found in the prevalence of prothrombin or methylenetetrahydrofolate reductase mutation. No factor V Leiden mutation was found. Another Italian group<sup>17</sup> found a strong and significant association of the prothrombin G20210A mutation (30% versus 2.5% in patients versus control subjects, respectively,  $P=0.001$ ; OR 16.2,  $P=0.002$ ) and hyperhomocysteinemia (43.3% versus 10%,  $P=0.002$ ; OR 6.9,  $P=0.002$ ).



**Figure 1.** Age and sex distribution of cerebral venous and sinus thrombosis (CVT) in adults. Bars represent the number of patients with CVT for the specific age/sex category. Data provided by Dr Jose Ferro from the International Study on Cerebral Venous and Dural Sinuses Thrombosis.

**Pregnancy and Puerperium**

Pregnancy and the puerperium are common causes of transient prothrombotic states.<sup>57</sup> Approximately 2% of pregnancy-associated strokes are attributable to CVT.<sup>31</sup> The frequency of CVT in the puerperium is estimated at 12 cases per 100 000 deliveries, only slightly lower than puerperal arterial stroke.<sup>58</sup>

In a study from Mexico, ≈50% of CVT occurred during pregnancy or puerperium.<sup>32</sup> Most pregnancy-related CVT occurs in the third trimester or puerperium. Seven of 8 CVTs among 50 700 admissions for delivery in Canada occurred postpartum.<sup>33</sup> During pregnancy and for 6 to 8 weeks after birth, women are at increased risk of venous thromboembolic events.<sup>34</sup> Pregnancy induces several prothrombotic changes in the coagulation system that persist at least during early puerperium. Hypercoagulability worsens after delivery as a result of volume depletion and trauma. During the puerperium, additional risk factors include infection and instrumental delivery or cesarean section. One study reported that the risk of peripartum CVT increased with increasing maternal age, increasing hospital size, and cesarean delivery, as well as in the presence of hypertension, infections, and excessive vomiting in pregnancy.<sup>35</sup> Recently, it was reported that in pregnant women, hyperhomocysteinemia was associated with increased risk of puerperal CVT (OR 10.8, 95% CI 4.0 to 29.4) in a study of 60 case subjects and 64 control subjects.<sup>30</sup>

**Oral Contraceptives**

A 1998 study compared the prevalence of several risk factors, including use of oral contraceptives, among 40 female patients with CVT, 80 female patients with DVT of the lower extremities, and 120 female control subjects.<sup>36</sup> Nearly all CVT case subjects were using oral contraceptives (96%), which conferred 22.1-fold increased odds of CVT (95% CI 5.9 to 84.2). The OR for women with the prothrombin G20210A mutation who used oral contraceptives was 149.3 (95% CI 31.0 to 711.0) compared with those with neither characteristic. Stratification for the presence of factor V Leiden or prothrombin mutation and the use

**Table 3. Predisposing Conditions for CVT and Principles in Favor of a Cause-and-Effect Relationship**

Condition	Prevalence, %*	Consistency <sup>1</sup> †	Strength of Association <sup>2</sup> ‡ OR (95% CI)	Biological Plausibility <sup>3</sup> ‡	Temporality <sup>4</sup> ‡	Biological Gradient <sup>5</sup> ‡
Prothrombotic conditions	34.1					
Antithrombin III deficiency		Yes <sup>12,13</sup>	NA	Yes	Yes	Yes‡
Protein C deficiency		Yes <sup>12,13</sup>	11.1 (1.9–66.0)	Yes	Yes	Yes‡
Protein S deficiency		Yes <sup>12,13</sup>	12.5 (1.5 to 107.3)	Yes	Yes	Yes‡
Antiphospholipid and anticardiolipin antibodies	5.9	Yes <sup>12,14,15*</sup>	8.8 (1.3–57.4)*	Yes	Yes	Yes‡
Resistance to activated protein C and factor V Leiden		Yes <sup>16–27</sup>	3.4 (2.3 to 5.1)	Yes	Yes	Yes‡
Mutation G20210A of factor II		Yes <sup>28</sup>	9.3 (5.9 to 14.7)	Yes	Yes	Yes <sup>28</sup> ‡
Hyperhomocysteinemia	4.5	Yes <sup>13,16,17,29,30</sup>	4.6 (1.6–12.0)	Yes	Yes	Yes <sup>13</sup>
Pregnancy and puerperium	21	Yes <sup>31–35</sup>	NA	Yes	Yes	NA
Oral contraceptives	54.3	Yes <sup>13,17,18,23,27,32,36–38</sup>	5.6 (4.0–7.9)*	Yes	Yes	Yes
Drugs						
Androgen, danazol, lithium, vitamin A, IV immunoglobulin, ecstasy	7.5		NA	Yes	Yes	NA
Cancer related	7.4	Yes <sup>39–41</sup>	NA	Yes	Yes	NA
Local compression						
Hypercoagulable						
Antineoplastic drugs (tamoxifen, L-asparaginase)						
Infection	12.3		NA	Yes	Yes	NA
Parameningeal infections (ear, sinus, mouth, face, and neck)		Yes <sup>42–44</sup>				
Mechanical precipitants	4.5	Yes <sup>45–47</sup>	NA	Yes	Yes	NA
Complication of epidural blood patch						
Spontaneous intracranial hypotension						
Lumbar puncture	1.9					
Other hematologic disorders	12	Yes <sup>48–51</sup>	NA	Yes	Yes	NA
Paroxysmal nocturnal hemoglobinuria						
Iron deficiency anemia		Yes	NA	Yes	Yes	NA
Nephrotic syndrome	0.6					
Polycythemia, thrombocythemia	2.8					
Systemic diseases	7.2	Yes <sup>52,53</sup>	NA	Yes	Yes	NA
Systemic lupus erythematosus	1					
Behçet disease	1					
Inflammatory bowel disease	1.6					
Thyroid disease	1.7					
Sarcoidosis	0.2					
Other	1.7					
None identified	12.5		NA	NA	NA	NA

CVT indicates cerebral venous thrombosis; OR, odds ratio; CI, confidence interval; NA, nonapplicable/nonavailable; and IV, intravenous.

\*Prevalence as per Ferro et al.<sup>10</sup> Percentages for CVT associated with oral contraceptives or pregnancy/puerperium are reported among 381 women ≤50 years of age.

†Cause-and-effect relationship determined as follows: (1) Consistency of association: Has the association been repeatedly observed by different investigators (yes/no)? (2) Strength of association: How strong is the effect (relative risk or OR)? (3) Biological plausibility: Does the association make sense, and can it be explained pathophysiologically (yes/no)? (4) Temporality: Does exposure precede adverse outcome (yes/no)? (5) Biological gradient: Does a dose-response relationship exist (yes/no)? Evidence of a strong and consistent association, evidence of biological plausibility, a notable risk of recurrent events, and detection of a biological gradient are suggestive of causation rather than association by chance alone. Modified from Grimes and Schulz<sup>54</sup> with permission of the publisher. Copyright © 2002, Elsevier.

‡Evidence for the biological gradient is not specific for CVT but for VTE: Anticardiolipins and CVT—based on a case-matched control study (Christopher et al)<sup>15</sup>; oral contraceptives—from Dentali et al<sup>28</sup>; cancer—results among 7029 patients with cancer, 20 of whom (0.3%) developed CVT, combined with results from Ferro et al (OR 27.9, 95% CI 16.5 to 47.2)<sup>10</sup>; hyperhomocysteinemia and CVT—Martinelli et al.<sup>13</sup> For patients with the prothrombin 20210 mutation, having a heterozygous mutation increases the risk of developing a first venous thrombotic event by approximately 2 to 3 times the background risk (or 2 to 3 in 1000 people each year). Having homozygous prothrombin mutations increases the risk further, but it is not yet well established how much the risk is increased (Varga et al).<sup>55</sup>

of oral contraceptives showed similar point estimates for the coagulation abnormalities alone and the use of oral contraceptives alone, whereas the presence of both risk factors gave an OR of 30.0 (95% CI 3.4 to 263.0) for factor V Leiden and 79.3 (95% CI 10.0 to 629.4) for the prothrombin mutation. A study in the Netherlands<sup>37</sup> found that of 40 female CVT patients, 85% used oral contraceptives, with an adjusted OR of 13 (95% CI 5 to 37). The combination of oral contraceptives with a prothrombotic condition also dramatically increased the risk of CVT. A study from Brazil showed similar results.<sup>18</sup> In a meta-analysis that included 16 studies, the authors reported an increased risk of CVT in oral contraceptive users (relative risk 15.9, 95% CI 6.98 to 36.2).<sup>59</sup> In another meta-analysis of 17 studies,<sup>28</sup> an increased risk of CVT was found in patients who used oral contraceptives (OR 5.59, 95% CI 3.95 to 7.91;  $P < 0.001$ ). It is clear that the use of oral contraceptives is associated with an increased risk of CVT, that the great majority of younger nonpregnant women with CVT are oral contraceptive users, and that the risk of CVT with oral contraceptive use in women is greater among those with a hereditary prothrombotic factor.

### Cancer

In the ISCVT,<sup>10</sup> 7.4% of cases of CVT were associated with cancer. It has been speculated that CVT could be more frequent in cancer patients, particularly in patients with hematologic malignancies; however, there are no studies with a control group. Potential mechanisms for an association of cancer with CVT include direct tumor compression, tumor invasion of cerebral sinuses,<sup>39–41</sup> or the hypercoagulable state associated with cancer.<sup>60</sup> Chemotherapeutic and hormonal agents used for cancer treatment may also play a role.

### Other Uncommon Causes

New neuroimaging procedures have increased the ability to detect CVT in recent years and have also helped to identify other potential causes, including infections, mainly in parameningeal locations (ear, sinus, mouth, face, and neck). These causes only explained 8.2% of all cases in the ISCVT series.<sup>2</sup> In contrast, CVT caused by infection is more common in children. In a recent series of 70 children with CVT in the United States, 40% had infection-related CVT.<sup>16</sup> Conversely, a French study of 62 adults with isolated lateral sinus thrombosis found that only 3 cases were related to parameningeal infections.<sup>42</sup>

Other conditions have been associated with CVT in case reports or small series, including paroxysmal nocturnal hemoglobinuria,<sup>48</sup> iron deficiency anemia,<sup>49</sup> thrombocytopenia,<sup>50</sup> heparin-induced thrombocytopenia,<sup>61</sup> thrombotic thrombocytopenic purpura,<sup>14</sup> nephrotic syndrome,<sup>51</sup> inflammatory bowel disease,<sup>10,62</sup> systemic lupus erythematosus,<sup>52</sup> Behçet disease,<sup>53</sup> mechanical precipitants, epidural blood patch,<sup>45</sup> spontaneous intracranial hypotension,<sup>46</sup> and lumbar puncture.<sup>47</sup>

## Clinical Diagnosis of CVT

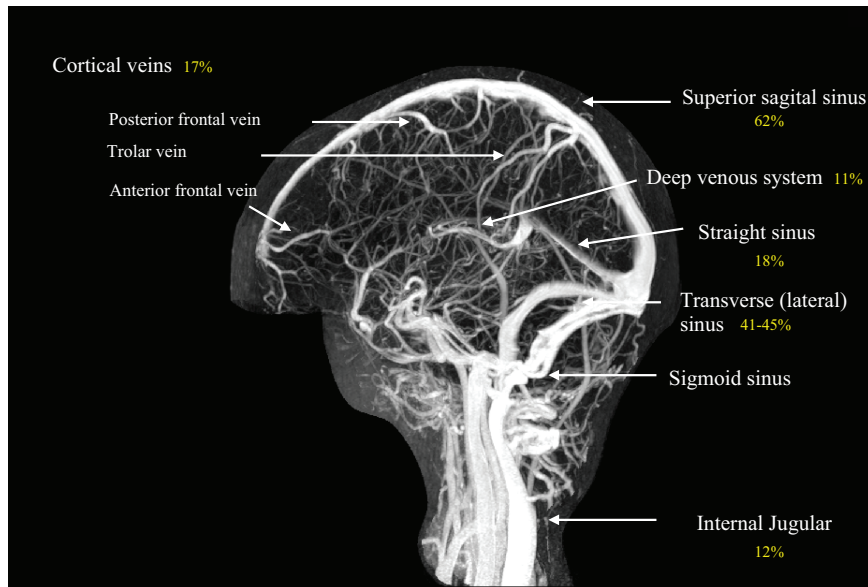
### Principal Clinical Findings

The diagnosis of CVT is typically based on clinical suspicion and imaging confirmation. Clinical findings in CVT usually fall into 2 major categories, depending on the mechanism of neurological dysfunction: (1) Those that are related to increased intracranial pressure attributable to impaired venous

drainage and (2) those related to focal brain injury from venous ischemia/infarction or hemorrhage. In practice, many patients have clinical findings due to both mechanisms, either at presentation or with progression of the underlying disease. Headache, generally indicative of an increase in intracranial pressure, is the most common symptom in CVT and was present in nearly 90% of patients in the ISCVT.<sup>10</sup> Similar headache frequency has been reported in other populations studied.<sup>63</sup> The headache of CVT is typically described as diffuse and often progresses in severity over days to weeks. A minority of patients may present with thunderclap headache, suggestive of subarachnoid hemorrhage, and a migrainous type of headache has been described.<sup>64</sup> Isolated headache without focal neurological findings or papilledema occurs in up to 25% of patients with CVT and presents a significant diagnostic challenge.<sup>65</sup> CVT is an important diagnostic consideration in patients with headache and papilledema or diplopia (caused by sixth nerve palsy) even without other neurological focal signs suggestive of idiopathic intracranial hypertension. When focal brain injury occurs because of venous ischemia or hemorrhage, neurological signs and symptoms referable to the affected region are often present; most common are hemiparesis and aphasia, but other cortical signs and sensory symptoms may occur. Psychosis, in conjunction with focal neurological signs, has also been reported.<sup>66</sup>

Clinical manifestations of CVT may also depend on the location of the thrombosis (Figure 2). The superior sagittal sinus is most commonly involved, which may lead to headache, increased intracranial pressure, and papilledema.<sup>67</sup> A motor deficit, sometimes with seizures, can also occur. Scalp edema and dilated scalp veins may be seen on examination.<sup>68</sup> For lateral sinus thromboses, symptoms related to an underlying condition (middle ear infection) may be noted, including constitutional symptoms, fever, and ear discharge. Pain in the ear or mastoid region and headache are typical. On examination, increased intracranial pressure and distention of the scalp veins may be noted. Hemianopia, contralateral weakness, and aphasia may sometimes be seen owing to cortical involvement.<sup>69</sup> Approximately 16% of patients with CVT have thrombosis of the deep cerebral venous system (internal cerebral vein, vein of Galen, and straight sinus), which can lead to thalamic or basal ganglionic infarction. Most patients present with rapid neurological deterioration. CVT may be confused with other medical conditions.<sup>70–75</sup> Cortical vein thrombosis is also uncommon, and specific clinical syndromes related to the larger cortical veins are rarely seen (eg, temporal lobe hemorrhage associated with vein of Labbé thrombosis).<sup>76</sup>

Several important clinical features distinguish CVT from other mechanisms of cerebrovascular disease. First, focal or generalized seizures are frequent, occurring in  $\approx 40\%$  of patients. Second, an important clinical correlate to the anatomy of cerebral venous drainage is that bilateral brain involvement is not infrequent. This is particularly notable in cases that involve the deep venous drainage system, when bilateral thalamic involvement may occur, causing alterations in level of consciousness without focal neurological findings. Bilateral motor signs, including paraparesis, may also be present due to sagittal sinus thrombosis and bihemispheric injury. Finally, patients with



**Figure 2.** Magnetic resonance venogram showing the cerebral venous system and most frequent (%) location of cerebral venous and sinus thrombosis, as reported in the International Study on Cerebral Venous and Dural Sinuses Thrombosis (n=624).<sup>44</sup>

CVT often present with slowly progressive symptoms. Delays in diagnosis of CVT are common and significant. In the ISCVT, symptom onset was acute (<48 hours) in 37% of patients, subacute (>48 hours to 30 days) in 56% of patients, and chronic (>30 days) in 7% of patients. The median delay from onset of symptoms to hospital admission was 4 days, and from symptom onset to diagnosis, it was 7 days.<sup>10</sup>

### Other Clinical and Laboratory Findings

#### Routine Blood Work

A complete blood count, chemistry panel, sedimentation rate, and measures of the prothrombin time and activated partial thromboplastin time are indicated for patients with suspected CVT. These studies may demonstrate abnormalities suggestive of an underlying hypercoagulable state, an infectious process, or an inflammatory state, all of which may contribute to the development of CVT.

#### Recommendations

1. In patients with suspected CVT, routine blood studies consisting of a complete blood count, chemistry panel, prothrombin time, and activated partial thromboplastin time should be performed (*Class I; Level of Evidence C*).
2. Screening for potential prothrombotic conditions that may predispose a person to CVT (eg, use of contraceptives, underlying inflammatory disease, infectious process) is recommended in the initial clinical assessment (specific recommendations for testing for thrombophilia are found in the long-term management section of this document) (*Class I; Level of Evidence C*).

#### Lumbar Puncture

Unless there is clinical suspicion of meningitis, examination of the cerebrospinal fluid (CSF) is typically not helpful in cases with focal neurological abnormalities and radiographic confirmation of the diagnosis of CVT. Elevated opening pressure is a frequent finding in CVT and is present in >80% of patients.<sup>10</sup> An elevated opening pressure may be a clue for diagnosing CVT in patients who present at the emergency department with

headaches. Elevated cell counts (found in ≈50% of patients) and protein levels (found in ≈35%) are often present, but their absence should not discourage consideration of the diagnosis of CVT.<sup>10</sup> There are no specific CSF abnormalities in CVT. Therapeutic considerations are described in “Management and Prevention of Early Complications (Hydrocephalus, Intracranial Hypertension, Seizures).”

#### D-Dimer

Measurement of D-dimer, a product of fibrin degradation, has a diagnostic role in exclusion of DVT or pulmonary embolus when used with pretest probability assessment. A number of small studies, all with methodological limitations, demonstrated high sensitivity for the identification of patients with CVT and a potential role for exclusion of the diagnosis, although this finding was not universal.<sup>77–81</sup> As is the case with its use in DVT and pulmonary embolism (PE), the specificity of D-dimer was poor, because there are many causes of elevated D-dimer. In a well-designed prospective, multicenter study of 343 patients presenting to the emergency department with symptoms that suggested CVT, a positive D-dimer level (defined as a level >500 μg/L) was found in 34 of 35 patients with confirmed CVT and 27 of 308 patients without CVT.<sup>82</sup> This yielded a sensitivity of 97.1%, a specificity of 91.2%, a negative predictive value of 99.6%, and a positive predictive value of 55.7%, which supports a clinically useful role of D-dimer in excluding CVT. A normal D-dimer level according to a sensitive immunoassay or rapid ELISA may help identify patients with a low probability of CVT.<sup>82,83</sup> A subsequent study of 73 patients with confirmed CVT found normal D-dimer levels in 7 patients (10%).<sup>83</sup> Five of the 7 patients with confirmed CVT and negative D-dimer presented with isolated headache, which suggests that this subgroup might be particularly at risk of false-negative results of D-dimer testing. In contrast, of the 57 patients with confirmed CVT who presented with isolated intracranial hypertension or encephalic signs, only 2 (3.5%) had negative D-dimer testing.

Several factors may account for some of the discrepant findings noted above. First, D-dimer levels decline with time from onset of symptoms, which suggests that patients who

present with subacute or chronic symptoms are more likely to have negative D-dimer levels.<sup>82</sup> Second, the anatomic extent of thrombosed sinuses may correlate with D-dimer levels, which suggests that patients with lesser clot burden may have false-negative D-dimer testing results.<sup>82</sup> Finally, a number of different D-dimer assays are available with variable test performance characteristics.

#### **Recommendation**

- 1. A normal D-dimer level according to a sensitive immunoassay or rapid enzyme-linked immunosorbent assay (ELISA) may be considered to help identify patients with low probability of CVT<sup>82,83</sup> (Class IIb; Level of Evidence B). If there is a strong clinical suspicion of CVT, a normal D-dimer level should not preclude further evaluation.**

#### **Common Pitfalls in the Diagnosis of CVT**

There are several clinical scenarios in which misdiagnosis, or delay in diagnosis, of CVT frequently occurs.

##### **Intracranial Hemorrhage**

Approximately 30% to 40% of patients with CVT present with ICH.<sup>14,84</sup> Identification of these patients is critical given that the pathophysiology underlying hemorrhage in such cases is distinct from other causes of ICH, and this has important treatment implications. Features suggestive of CVT as a cause of ICH include prodromal headache (which is highly unusual with other causes of ICH), bilateral parenchymal abnormalities, and clinical evidence of a hypercoagulable state. These features may not be present, however, and a high index of clinical suspicion is necessary. Isolated subarachnoid hemorrhage may also occur due to CVT, although this is rare (0.8% of patients in ISCVT). Hemorrhage location is an important consideration in estimating the likelihood of CVT and is discussed elsewhere in this statement (see “Imaging in the Diagnosis of CVT” for further details).

#### **Recommendation**

- 1. In patients with lobar ICH of otherwise unclear origin or with cerebral infarction that crosses typical arterial boundaries, imaging of the cerebral venous system should be performed (Class I; Level of Evidence C).**

##### **Isolated Headache/Idiopathic Intracranial Hypertension**

In 1 series, 25% of patients with CVT presented with isolated headache, and another 25% presented with headache in conjunction with papilledema or sixth nerve palsies suggestive of idiopathic intracranial hypertension.<sup>65</sup> In a series of 131 patients who presented with papilledema and clinically suspected idiopathic intracranial hypertension, 10% had CVT when magnetic resonance imaging (MRI)/magnetic resonance venography (MRV) was performed.<sup>85</sup> Imaging of the cerebral venous system has been recommended for all patients with the clinical picture of idiopathic intracranial hypertension, because the distinction between CVT and idiopathic intracranial hypertension has important prognostic and treatment implications, and the yield of imaging is significant.<sup>67,85</sup> For patients with isolated headache, the proper strategy for identification of CVT is much less clear. Headache is an extremely common symptom, and the vast

majority of patients with isolated headache will not have CVT. The cost-effectiveness and yield of routine imaging are highly uncertain. Factors that may suggest the diagnosis, and thus prompt imaging evaluation, include a new, atypical headache; headache that progresses steadily over days to weeks despite conservative treatment; and thunderclap headache.<sup>64</sup> In addition, a greater level of clinical suspicion for CVT should be maintained in patients with a hypercoagulable state.

#### **Recommendations**

- 1. In patients with the clinical features of idiopathic intracranial hypertension, imaging of the cerebral venous system is recommended to exclude CVT (Class I; Level of Evidence C).**
- 2. In patients with headache associated with atypical features, imaging of the cerebral venous system is reasonable to exclude CVT (Class IIa; Level of Evidence C).**

##### **Isolated Mental Status Changes**

Occasionally, patients with CVT will present with somnolence or a confusional state in the absence of obvious focal neurological abnormalities.<sup>86–88</sup> Such clinical presentations are more common in the elderly and with thrombosis of the deep venous system.<sup>89,90</sup> Although a number of mechanisms may underlie this clinical presentation, an important cause is bilateral thalamic lesions due to involvement of the deep venous system. Computed tomography (CT) scanning, especially if performed early in the clinical course, may be unremarkable; MRI will usually demonstrate abnormalities in such cases.

#### **Imaging in the Diagnosis of CVT**

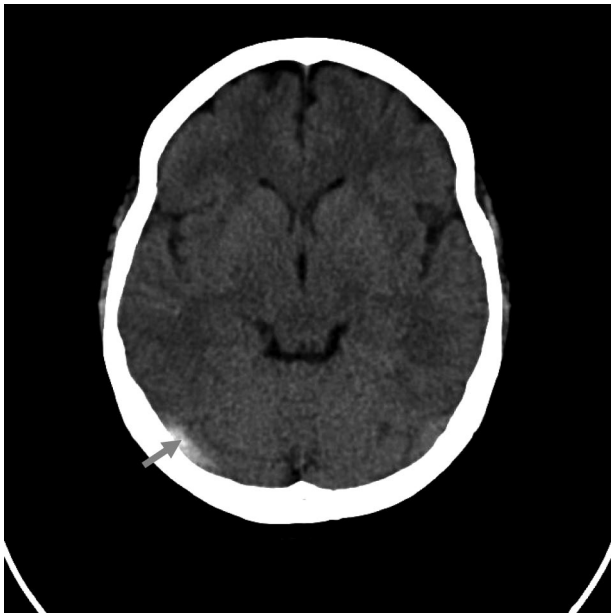
Over the past 2 decades, diagnostic imaging has played an increasing role in the diagnosis and management of CVT.<sup>2,3,55,91–97</sup> Diagnostic imaging of CVT may be divided into 2 categories, which will be reviewed in more detail below: Noninvasive modalities and invasive modalities. The goal is to determine vascular and parenchymal changes associated with this medical condition. In some cases, the diagnosis is made only with cerebral digital subtraction angiography.<sup>72,91,98–100</sup>

#### **Noninvasive Diagnostic Modalities: CT, MRI, and Ultrasound**

##### **Computed Tomography**

CT is widely used as the initial neuroimaging test in patients who present with new-onset neurological symptoms such as headache, seizure, mental alteration, or focal neurological signs. CT without contrast is often normal but may demonstrate findings that suggest CVT.<sup>92,93</sup> Anatomic variability of the venous sinuses makes CT diagnosis of CVT insensitive, with results on a plain CT being abnormal only in ≈30% of CVT cases.<sup>1,28,70,94,95,98</sup> The primary sign of acute CVT on a noncontrast CT is hyperdensity of a cortical vein or dural sinus. Acutely thrombosed cortical veins and dural sinuses appear as a homogenous hyperdensity that fills the vein or sinus and are most clearly visualized when CT slices are perpendicular to the dural sinus or vein (Figure 3). However, only approximately one third of CVT demonstrates direct signs of hyperdense dural sinus.<sup>70,94,96</sup> Thrombosis of the posterior portion of the superior sagittal sinus may appear as





**Figure 3.** Noncontrast computed tomography head scan showed spontaneous hyperdensity of right transverse sinus.

a dense triangle, the dense or filled delta sign. An ischemic infarction, sometimes with a hemorrhagic component, may be seen. An ischemic lesion that crosses usual arterial boundaries (particularly with a hemorrhagic component) or in close

proximity to a venous sinus is suggestive of CVT.<sup>93</sup> Subarachnoid hemorrhage and ICH are infrequent.<sup>99</sup> Subarachnoid hemorrhage was found in only 0.5% to 0.8% of patients with CVT,<sup>10,14,99</sup> and when present, it was localized in the convexity as opposed to the area of the circle of Willis usually observed in patients with aneurysmal rupture.

Contrast-enhanced CT may show enhancement of the dural lining of the sinus with a filling defect within the vein or sinus. Contrast-enhanced CT may show the classic “empty delta” sign, in which a central hypointensity due to very slow or absent flow within the sinus is surrounded by contrast enhancement in the surrounding triangular shape in the posterior aspect of the superior sagittal sinus.<sup>93</sup> This finding may not appear for several days after onset of symptoms but does persist for several weeks.

Because symptoms of CVT may be overlooked or associated with delays in seeking medical attention, CVT may be seen only during the subacute or chronic stage. Compared with the density of adjacent brain tissue, thrombus may be isodense, hypodense, or of mixed density. In this situation, contrast CT or CT venography (CTV) may assist the imaging diagnosis.<sup>70–74,94,97,100–105</sup>

**Magnetic Resonance Imaging**

In general, MRI is more sensitive for the detection of CVT than CT at each stage after thrombosis (Table 4; Figure 4).<sup>1,70,96,97,101,106,107</sup> CVT is diagnosed on MRI with the

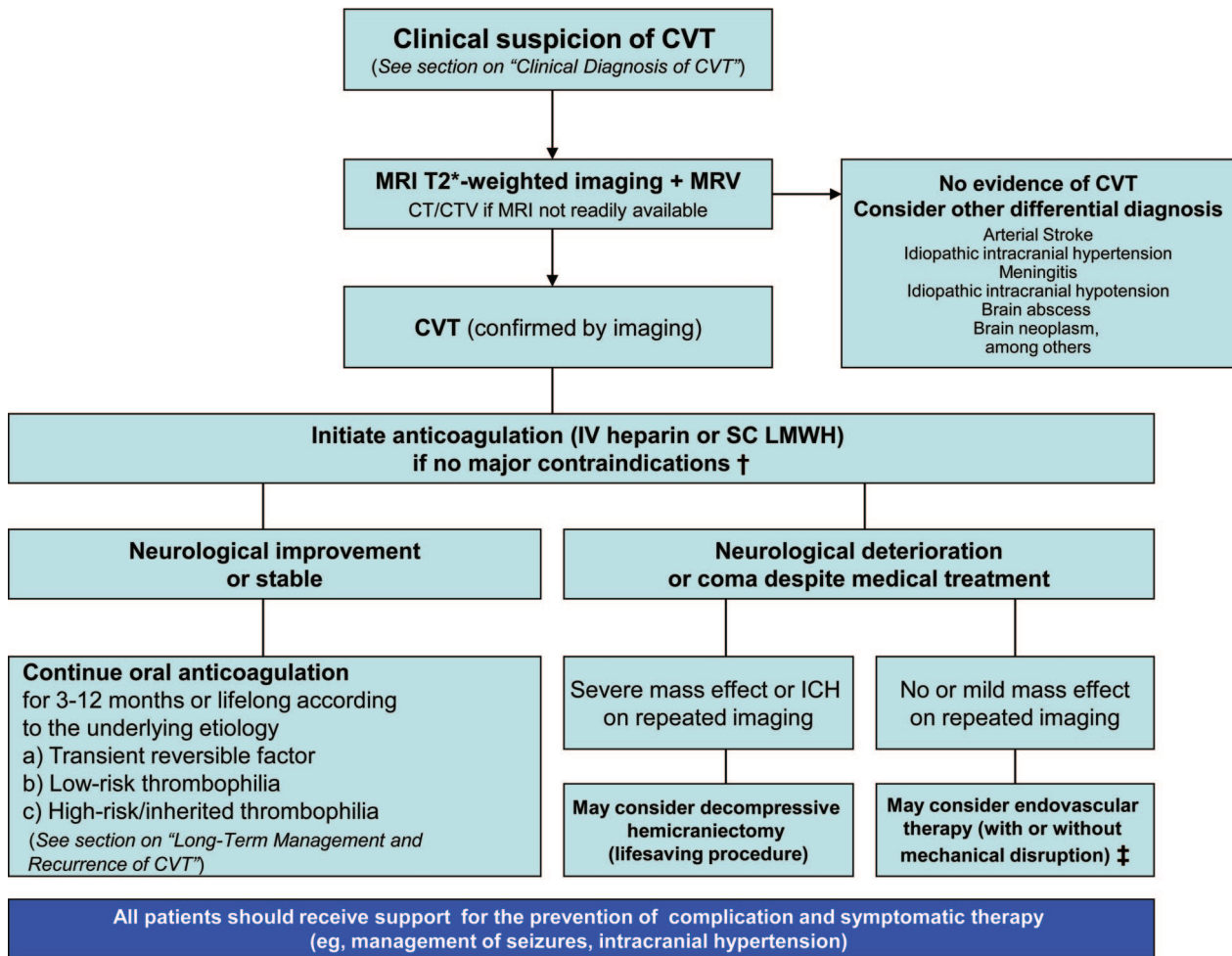
**Table 4. Comparison of the Advantages and Disadvantages of CT and MRI in the Diagnosis of CVT**

	CT+CTV	MRI+MRV
Advantages	<ul style="list-style-type: none"> <li>Good visualization of major venous sinuses</li> <li>Quick (5–10 min)</li> <li>Readily available</li> <li>Fewer motion artifacts</li> <li>Can be used in patients with a pacemaker, defibrillator, or claustrophobia</li> </ul>	<ul style="list-style-type: none"> <li>Visualization of the superficial and deep venous systems</li> <li>Good definition of brain parenchyma</li> <li>Early detection of ischemic changes</li> <li>No radiation exposure</li> <li>Detection of cortical and deep venous thrombosis</li> <li>Detection of macrobleeding and microbleeding</li> </ul>
Disadvantages	<ul style="list-style-type: none"> <li>Exposure to ionizing radiation</li> <li>Risk of contrast reactions</li> <li>Risk of iodinated contrast nephropathy (eg, in patients with diabetes, renal failure)</li> <li>Low resolution for small parenchymal abnormalities</li> <li>Poor detection of cortical and deep venous thrombosis</li> </ul>	<ul style="list-style-type: none"> <li>Time consuming</li> <li>Motion artifacts</li> <li>Availability</li> <li>Limited use in patients with cardiac pacemaker or claustrophobia</li> <li>Confers a low risk of gadolinium-induced nephrogenic systemic fibrosis</li> <li>Slow flow states, complex flow patterns, and normal anatomic variations in dural sinus flow can affect the interpretation</li> </ul>
Sensitivity/specificity	<ul style="list-style-type: none"> <li>Small studies comparing multiplanar CT/CTV vs DSA showed 95% sensitivity and 91% specificity*</li> <li>Overall accuracy 90% to 100%, depending on vein or sinus</li> </ul>	<ul style="list-style-type: none"> <li>The sensitivity and specificity of MRI/MRV are not known owing to the lack of large MRI/MRV head-to-head studies with DSA.</li> <li>Echoplanar T2 susceptibility-weighted imaging combined with MRV are considered the most sensitive sequences</li> </ul>
Practical application	<ul style="list-style-type: none"> <li>Acute onset of symptoms</li> <li>Emergency setting</li> <li>Multidetector CTV can be used as the initial test when MRI is not readily available</li> </ul>	<ul style="list-style-type: none"> <li>Acute or subacute onset of symptoms</li> <li>Emergency or ambulatory setting</li> <li>Patients with suspected CVT and normal CT/CTV</li> <li>In patients with suspected deep CVT, because complex basal dural sinuses and their emissary channels are more commonly seen</li> </ul>

CT indicates computed tomography; MRI, magnetic resonance imaging; CVT, cerebral venous thrombosis; CTV, CT venography; MRV, magnetic resonance venography; and DSA, digital subtraction angiography. \*Wetzel et al.<sup>93</sup>

Downloaded from http://stroke.ahajournals.org/ by guest on March 18, 2018

## Proposed Algorithm for the Management of CVT



**Figure 4.** Proposed algorithm for the management of CVT. The CVT writing group recognize the challenges facing primary care, emergency physicians and general neurologists in the diagnosis and management of CVT. The aim of this algorithm is to provide guidance to physicians in the initial management of CVT. Anticoagulation remains the principal therapy and is aimed at preventing thrombus propagation and increasing recanalization. This algorithm is not comprehensive, nor applicable to all clinical scenarios and patient management must be individualized. Limited evidence is available on the benefits of decompressive hemicraniectomy and endovascular therapy for the management of CVT as reflected by the low grade and level of recommendations. Anticipated future advances in imaging techniques, new pharmacological agents and endovascular procedures may provide other therapeutic alternatives to be considered in patients with CVT, and in the future these guidelines will be periodically updated to reflect the changing evidence. CVST indicates cerebral venous and sinus thrombosis; LMWH, low molecular weight heparin; Tx, therapy; ICH, intracerebral hemorrhage; CTV, CT venogram; MRV, MR venogram.

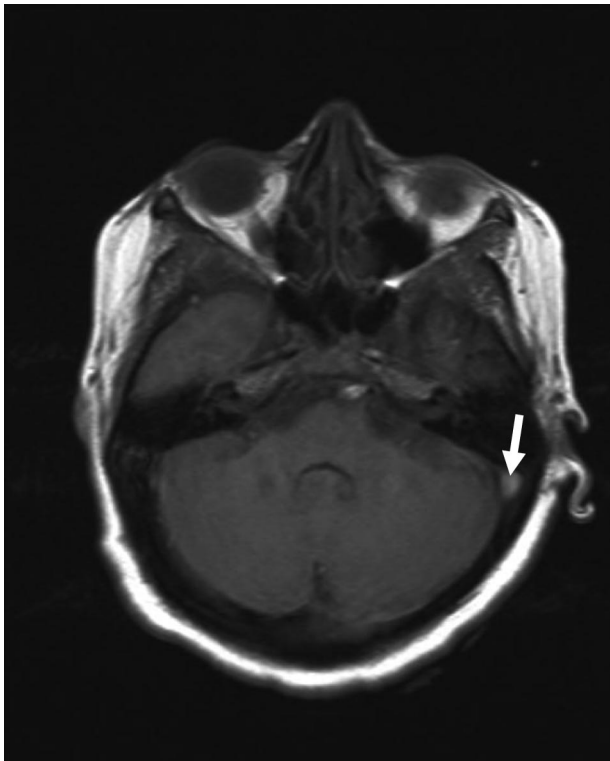
†Intracranial hemorrhage that occurred as the consequence of CVST is not a contraindication for anticoagulation.

‡Endovascular therapy may be considered in patients with absolute contraindications for anticoagulation therapy or failure of initial therapeutic doses of anticoagulant therapy.

detection of thrombus in a venous sinus. Findings are variable but may include a “hyperintense vein sign.”<sup>105,108–113</sup> Isolated cortical venous thrombosis is identified much less frequently than sinus thrombosis. The magnetic resonance signal intensity of venous thrombus varies according to the time of imaging from the onset of thrombus formation.<sup>6,65,94,101–107</sup> Acute thrombus may be of low intensity. In the first week, venous thrombus frequently appears as isointense to brain tissue on T1-weighted images and hypointense on T2-weighted images owing to increased deoxyhemoglobin. By the second week, thrombus contains methemoglobin, which results in hyperintensity on T1- and T2-weighted images (Figure 5).<sup>2,10,42,70,71,73,74,91,98–100,105,106,108,113–128</sup> With evolution of the thrombus, the paramagnetic products of deoxyhe-

moglobin and methemoglobin are present in the sinus. A thrombosed dural sinus or vein may then demonstrate low signal on gradient-echo and susceptibility-weighted images of magnetic resonance images.<sup>70,119,129</sup>

The principal early signs of CVT on non-contrast-enhanced MRI are the combination of absence of a flow void with alteration of signal intensity in the dural sinus. MRI of the brain is suggestive of CVT by the absence of a fluid void signal in the sinus, T2 hypointensity suggestive of a thrombus, or a central isodense lesion in a venous sinus with surrounding enhancement.<sup>120</sup> This appearance is the MRI equivalent of the CT empty delta sign. An acute venous thrombus may have hypointense signal that mimics a normal flow void. The nature of the thrombus then evolves through a subacute and chronic phase.<sup>128</sup>

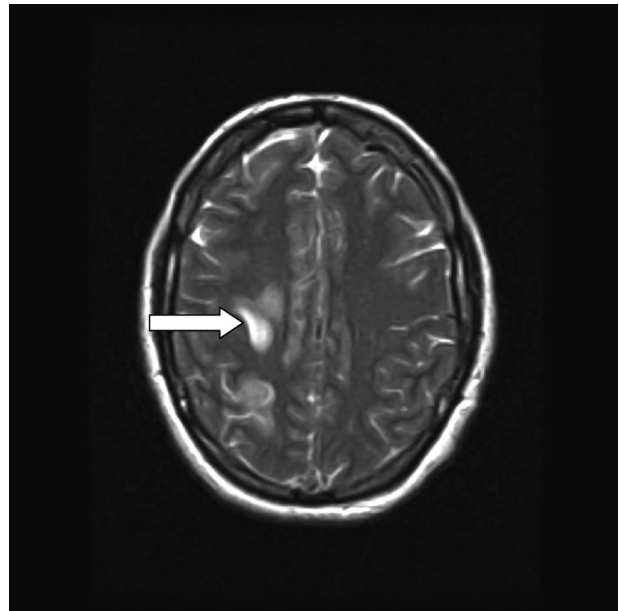


**Figure 5.** Flair magnetic resonance image showing hypersensitivity signal at left sigmoid sinus (arrow).

Thus, contrast-enhanced MRI and either CTV or MRV may be necessary to establish a definite diagnosis.

The secondary signs of MRI may show similar patterns to CT, including cerebral swelling, edema, and/or hemorrhage.<sup>91,130–134</sup> Occasionally, diffusion-weighted imaging (DWI) and perfusion-weighted MRI may assist in making the diagnosis. DWI may show high signal intensity as restricted diffusion- and perfusion-weighted MRI with prolonged transit time.<sup>70,104,107,109,110,115,120,124,130–135</sup>

Brain parenchymal lesions of CVT are better visualized and depicted on MRI than at CT (Figure 6). Focal edema without hemorrhage is visualized on CT in  $\approx 8\%$  of cases and on MRI in 25% of cases.<sup>70,95,102,111,119,128,133,136–138</sup> Focal parenchymal changes with edema and hemorrhage may be identified in up to 40% of patients.<sup>70,73,98,110,111,120,128,138</sup> The discrepancy in frequency of detection may be due in part to varying timing of imaging after thrombosis.<sup>2,10,14,70,74,95,128,139</sup> Petechial or confluent hemorrhage may also represent an underlying hemorrhagic venous infarction. This may include DWI abnormalities consistent with acute infarction, but the degree of DWI findings may be reduced in venous infarction compared with arterial infarction (Figure 7).<sup>124</sup> An altered enhancement pattern suggestive of collateral flow or of venous congestion may be seen. There are some characteristic patterns of brain parenchymal changes that distinguish CVT from other entities. Also, to some extent, lesions related to specific sinuses are regionally distributed. Brain parenchymal changes in frontal, parietal, and occipital lobes usually correspond to superior sagittal sinus thrombosis (Figure 8). Temporal lobe parenchymal changes correspond to lateral (transverse) and sigmoid sinus thrombosis. Deep parenchymal abnormalities, including tha-

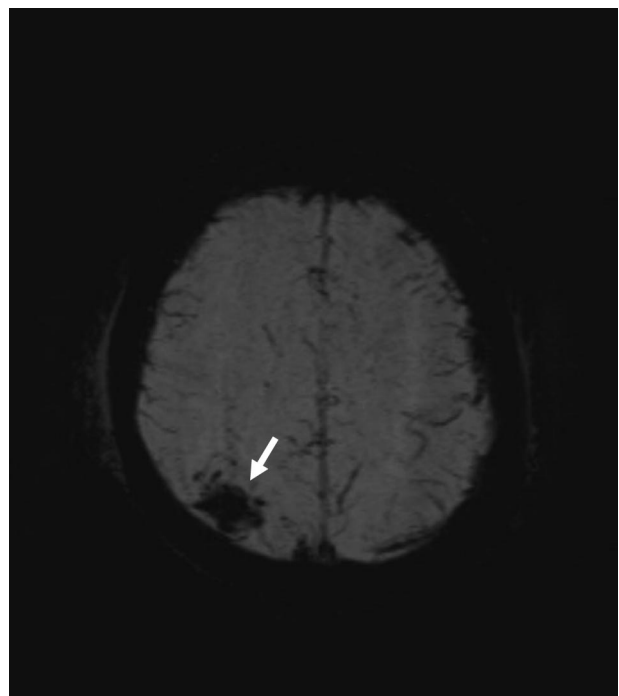


**Figure 6.** T2-weighted magnetic resonance image showing high-intensity bland venous infarct in frontal lobe.

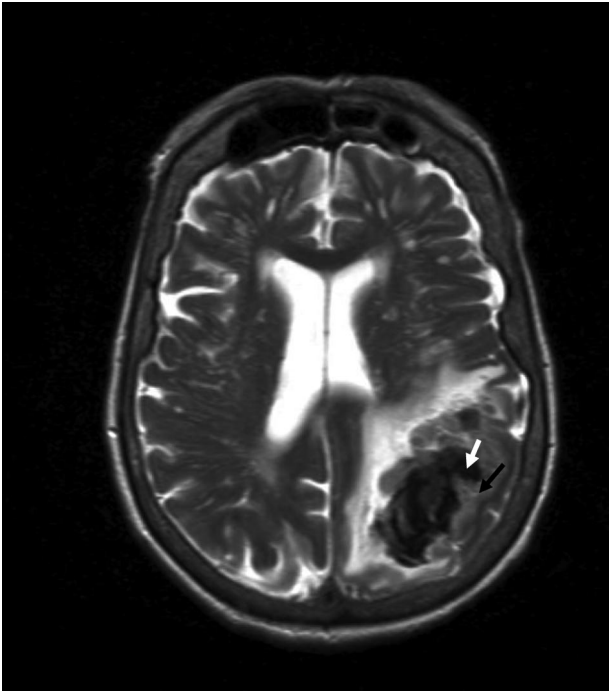
lamic hemorrhage, edema, or intraventricular hemorrhage, correspond to thrombosis of the vein of Galen or straight sinus. MRI signal can also predict radiographic outcome to some extent, because DWI abnormality within veins or sinus predicts poor recanalization.<sup>71,105,110,117–119,131–133,135,140,141</sup>

#### *CT Venography*

CTV can provide a rapid and reliable modality for detecting CVT (Figure 9). CTV is much more useful in subacute or chronic situations because of the varied density in thrombosed

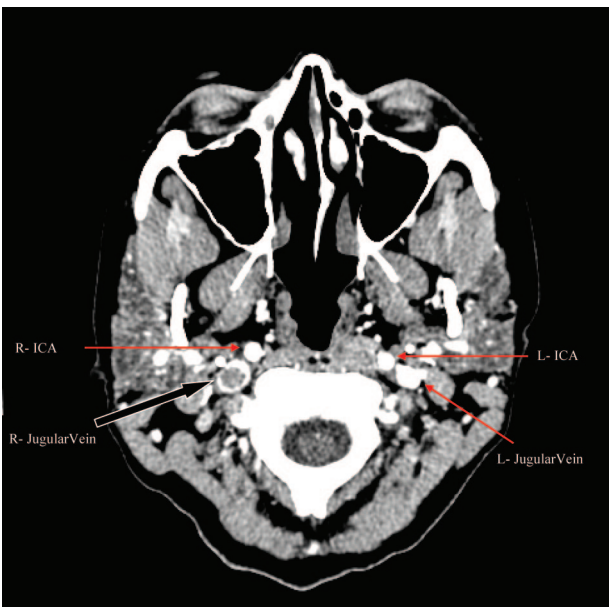


**Figure 7.** Susceptibility-weighted magnetic resonance image showing hemorrhagic venous infarct in the right parietal lobe.

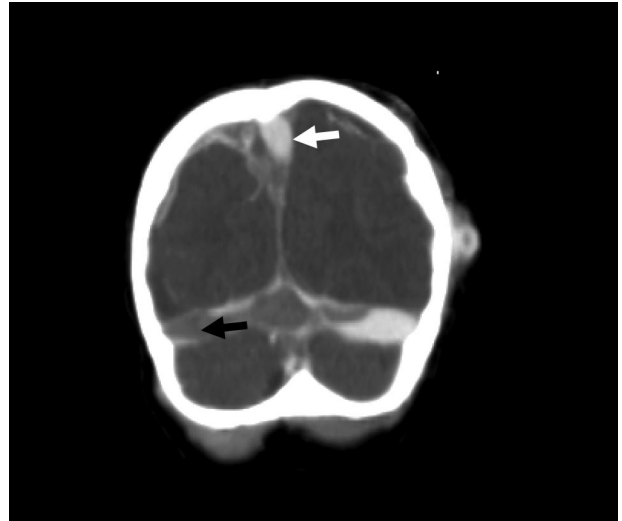


**Figure 8.** T2-weighted magnetic resonance image showing mixed hypointensity (white arrow) and isointensity (black arrow) signals representing an acute hemorrhage at left parietal lobe.

sinus (Figure 10). Because of the dense cortical bone adjacent to dural sinus, bone artifact may interfere with the visualization of enhanced dural sinus. CTV is at least equivalent to MRV in the diagnosis of CVT.<sup>94,97,100,101,103,106</sup> However, drawbacks to CTV include concerns about radiation exposure, potential for iodine contrast material allergy, and issues related to use of contrast in the setting of poor renal function.<sup>2,70,72,74,97,99–101,103,109,115,116,141</sup>



**Figure 9.** Computed tomographic venogram (axial) showing extension of the cerebral venous thrombosis down to the jugular vein (black arrow). R-ICA indicates right internal carotid artery; L-ICA, left internal carotid artery; R, right; and L, left.

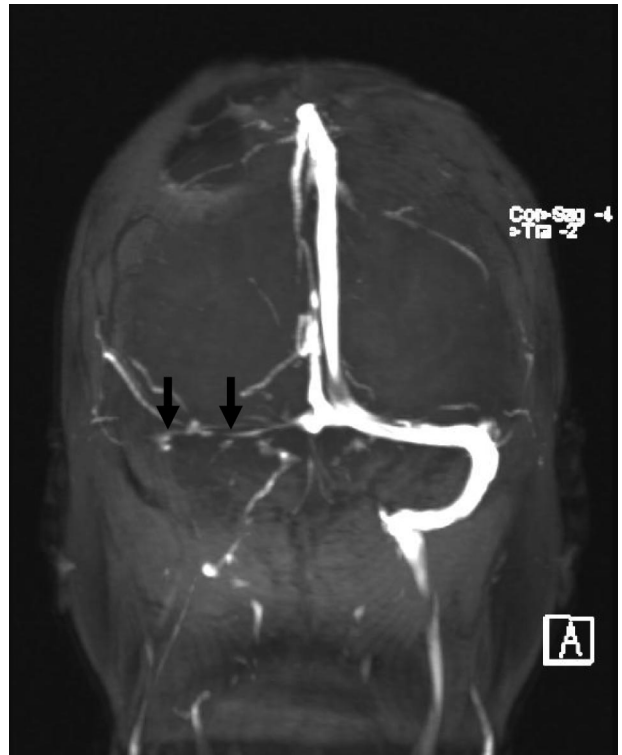


**Figure 10.** Computed tomographic venogram showing mixed density within venous sinuses (high-density contrast in patent segments (white arrow) and low density (black arrow) in nonperfusing thrombosed segments).

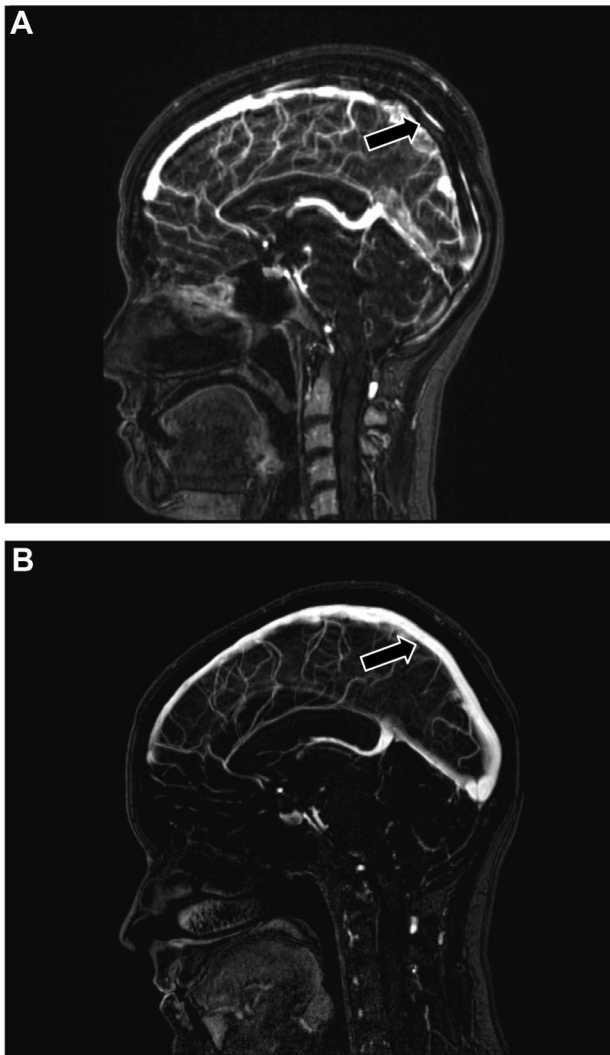
In some settings, MRV is preferable to CTV because of these concerns (Table 4).

**Magnetic Resonance Venography**

The most commonly used MRV techniques are time-of-flight (TOF) MRV (Figures 11 and 12) and contrast-enhanced magnetic resonance. Phase-contrast MRI is used less frequently, because defining the velocity of the encoding parameter is both difficult and operator-dependent.



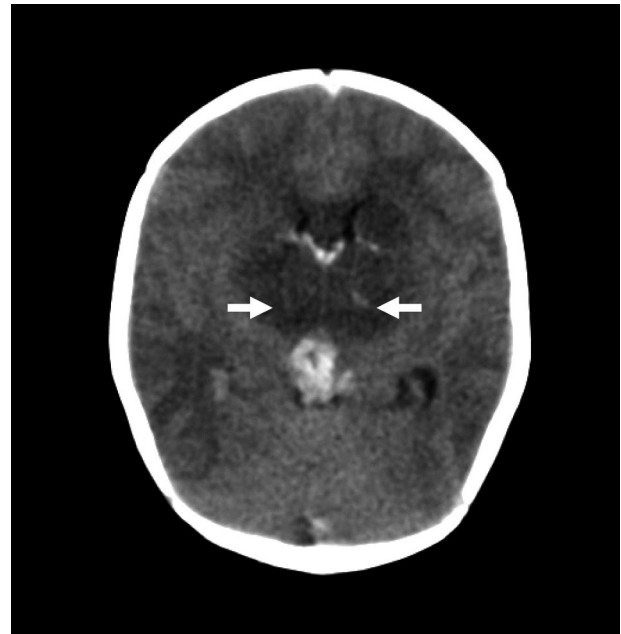
**Figure 11.** Magnetic resonance venography confirmed thrombosis (black arrows) of right transverse and sigmoid sinuses and jugular vein.



**Figure 12.** Magnetic resonance venogram showing thrombosis (black arrows) of the superior sagittal sinus and sigmoid sinuses. **A**, 2 days after symptom onset. **B**, 1 year follow-up after oral anticoagulation therapy (OAC).

The 2-dimensional TOF technique is the most commonly used method currently for the diagnosis of CVT, because 2-dimensional TOF has excellent sensitivity to slow flow compared with 3-dimensional TOF. It does have several potential pitfalls in imaging interpretation (see “Potential Pitfalls in the Radiological Diagnosis of CVT: Anatomic Variants, Thrombus Signal Variability, and Imaging Artifacts” below).<sup>2,71,72,95,97,106,108,109,125,142–150</sup> Despite the challenges, other sequences such as gradient echo, susceptibility-weighted imaging, and contrast MRI/MRV may assist in these situations.<sup>129,151</sup> Nonthrombosed hypoplastic sinus will not have abnormal low signal in the sinus on gradient echo or susceptibility-weighted images. The chronic thrombosed hypoplastic sinus will have marked enhanced sinus and no flow on 2-dimensional TOF venography. Contrast-enhanced MRI offers improved visualization of cerebral venous structures.

In patients with persistent or progressive symptoms despite medical treatment, repeated neuroimaging (including a CTV or MRV) may help identify the development of a new



**Figure 13.** Noncontrast computed tomographic scan in a newborn with deep cerebral venous thrombosis and bilateral thalamic (white arrows) infarcts.

ischemic lesion, ICH, edema, propagation of the thrombus, or other brain parenchymal lesions.<sup>97,110,111,120,128,136–138,140,141</sup>

#### **Deep CVT**

The deep venous system is readily seen on CT and MRI and may be less impacted by artifact because of the separation from bony structures (Figure 13). A potential pitfall at the junction of the straight sinus and vein of Galen on TOF MRI is the appearance of absence of flow if image acquisition is in an axial plane to the skull. This pitfall may be overcome with contrast-enhanced MRI and DWI.<sup>70–74,102,120,123,124</sup> Table 4 compares the advantages and disadvantages of CT/CTV and MRI/MRV.

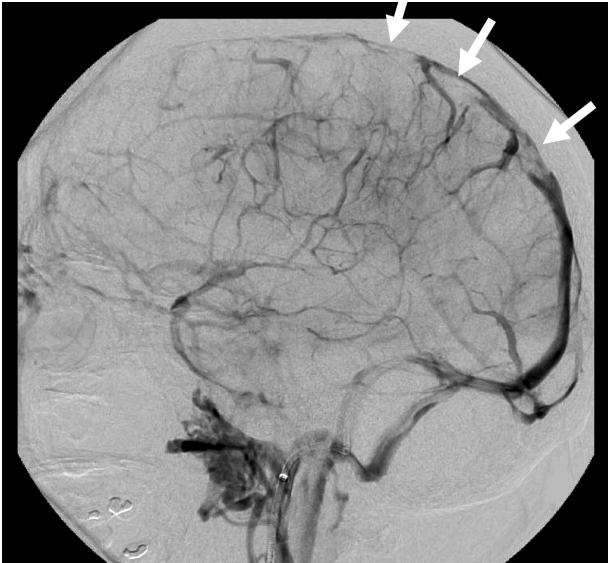
#### **Invasive Diagnostic Angiographic Procedures**

##### **Cerebral Angiography and Direct Cerebral Venography**

Invasive cerebral angiographic procedures are less commonly needed to establish the diagnosis of CVT given the availability of MRV and CTV.<sup>109,125,133</sup> These techniques are reserved for situations in which the MRV or CTV results are inconclusive or if an endovascular procedure is being considered.

##### **Cerebral Angiography**

Arteriographic findings include the failure of sinus appearance due to the occlusion; venous congestion with dilated cortical, scalp, or facial veins; enlargement of typically diminutive veins from collateral drainage; and reversal of venous flow. The venous phase of cerebral angiography will show a filling defect in the thrombosed cerebral vein/sinus (Figure 14). Because of the highly variable cerebral venous structures and inadequate resolution, CT or MRI may not provide adequate visualization of selected veins, especially cortical veins and in some situations the deep venous structures. Hypoplasia or atresia of cerebral veins or dural sinuses may lead to inconclusive results on MRV or CTV and can be clarified on the venous phase of cerebral angiography. Acute



**Figure 14.** Venous phase of direct carotid angiogram and catheter venogram showed extensive thrombosed superior sagittal sinus (white arrows) and cortical veins. The direct venogram also showed collateral cortical veins.

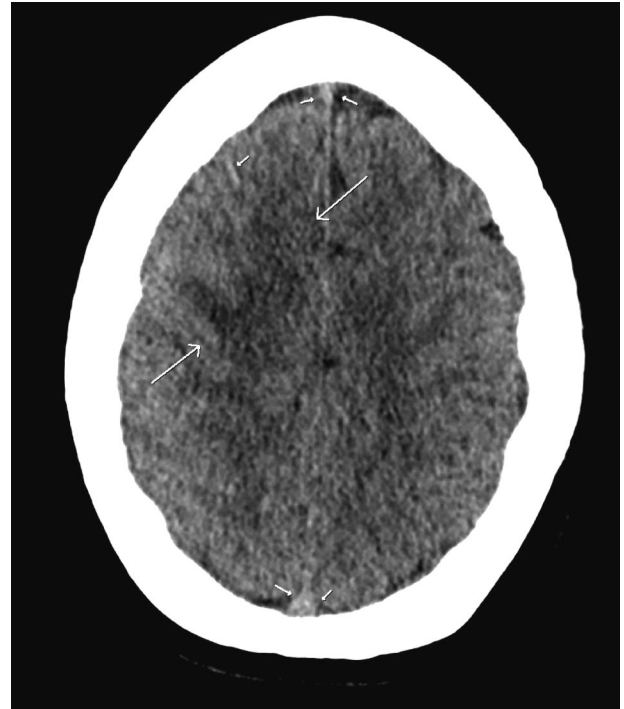
dural sinus and cortical vein thrombosis typically causes a delay in cerebral venous circulation, and cerebral angiography will demonstrate delayed and slow visualization of cerebral venous structures. Normally, the early veins begin to opacify at 4 to 5 seconds after injection of contrast material into the carotid artery, and the complete cerebral venous system is opacified in 7 to 8 seconds.<sup>74,91,124,152</sup> If cerebral veins or dural sinuses are not visualized in the normal sequences of cerebral angiography, the possibility of acute thrombosis is suspected. This finding accounts for the observed delayed cerebral perfusion seen with perfusion-weighted MRI with prolonged transit time.<sup>74,91,104,124,130,132,153</sup>

#### *Direct Cerebral Venography*

Direct cerebral venography is performed by direct injection of contrast material into a dural sinus or cerebral vein from microcatheter insertion via the internal jugular vein. Direct cerebral venography is usually performed during endovascular therapeutic procedures.<sup>74,91</sup> In direct cerebral venography, intraluminal thrombus is seen either as a filling defect within the lumen in the setting of nonocclusive thrombosis or as complete nonfilling in occlusive thrombosis. Complete thrombosis may also demonstrate a “cupping appearance” within the sinus. Venous pressure measurements may be performed during direct cerebral venography to identify venous hypertension. Normal venous sinus pressure is <10 mm H<sub>2</sub>O. The extent of parenchymal change correlates with increased venous pressure and with the stage of thrombosis, with changes being maximal in acute thrombosis.

#### *Other Diagnostic Modalities*

Transfontanelar ultrasound may be used to evaluate pediatric patients, including newborn or young infants with open anterior or posterior fontanels. Ultrasound, along with transcranial Doppler, may be useful to support the diagnosis of CVT and for ongoing monitoring of thrombus and parenchymal changes.<sup>152,154,155</sup>



**Figure 15.** Superior sagittal sinus thrombosis. CT Head showing a subtle decreased attenuation at right frontal lobe (arrows), an isodensity in superior sagittal sinus (short arrows) and right frontal cortical vein (a short arrow).

#### **Perfusion Imaging Methods**

Anecdotal evidence using positron emission tomography showed a reduction of the cerebral blood flow after ligation of the superior sagittal sinus with a concomitant venous infarction.<sup>156</sup> An increased regional cerebral blood volume was also observed in a young adult with sagittal sinus thrombosis.<sup>157</sup> A prolonged mean transit time and increased cerebral blood volume have been suggested as venous congestion, contrary to the pattern observed in patients with an ischemic arterial stroke (prolonged mean transit time with reduction in cerebral blood volume).<sup>111,124</sup>

#### **Potential Pitfalls in the Radiological Diagnosis of CVT: Anatomic Variants, Thrombus Signal Variability, and Imaging Artifacts**

The positive findings of intraluminal thrombus are the key to a confident diagnosis of CVT by CT or MRI. Unfortunately, these findings are not always evident, and the diagnosis rests on nonfilling of a venous sinus or cortical vein (Figure 15). Given the variation in venous anatomy, it is sometimes impossible to exclude CVT on noninvasive imaging studies. Anatomic variants of normal venous anatomy may mimic sinus thrombosis, including sinus atresia/hypoplasia, asymmetrical sinus drainage, and normal sinus filling defects related to prominent arachnoid granulations or intrasinus septa.<sup>2,71,72,95,97,106,108,109,125,142–150,158</sup> Angiographic examination of 100 patients with no venous pathology<sup>159</sup> showed a high prevalence of asymmetrical lateral (transverse) sinuses (49%) and partial or complete absence of 1 lateral sinus (20%).

Flow gaps are commonly seen on TOF MRV images, which sometimes affects their interpretation. The hypoplastic

dural sinus may have a more tapering appearance than an abrupt defect in contrast-enhanced images of the sinus. The lack of identification of a thrombus within the venous sinus on MRI or contrast-enhanced MRV or CTV is helpful to clarify the diagnosis.<sup>160</sup>

As mentioned, sinus signal-intensity variations may also affect the interpretation of imaging in the diagnosis of CVT.<sup>70</sup> Direct cerebral venography may be difficult to interpret owing to retrograde flow of contrast from the point of injection, and the venous pressure may not be accurate because of relative compartmentalization within the system.<sup>70</sup>

### Recommendations

1. Although a plain CT or MRI is useful in the initial evaluation of patients with suspected CVT, a negative plain CT or MRI does not rule out CVT. A venographic study (either CTV or MRV) should be performed in suspected CVT if the plain CT or MRI is negative or to define the extent of CVT if the plain CT or MRI suggests CVT (Class I; Level of Evidence C).
2. An early follow-up CTV or MRV is recommended in CVT patients with persistent or evolving symptoms despite medical treatment or with symptoms suggestive of propagation of thrombus (Class I; Level of Evidence C).
3. In patients with previous CVT who present with recurrent symptoms suggestive of CVT, repeat CTV or MRV is recommended (Class I; Level of Evidence C).
4. Gradient echo T2 susceptibility-weighted images combined with magnetic resonance can be useful to improve the accuracy of CVT diagnosis<sup>70,129,151</sup> (Class IIa; Level of Evidence B).
5. Catheter cerebral angiography can be useful in patients with inconclusive CTV or MRV in whom a clinical suspicion for CVT remains high (Class IIa; Level of Evidence C).
6. A follow-up CTV or MRV at 3 to 6 months after diagnosis is reasonable to assess for recanalization of the occluded cortical vein/sinuses in stable patients (Class IIa; Level of Evidence C).

## Management and Treatment

### Acute Management and Treatment of CVT

To address treatment of CVT in adults, we reviewed systematic reviews and guideline statements of the Cochrane Collaboration,<sup>161</sup> the American College of Chest Physicians,<sup>162,163</sup> and the European Federation of Neurological Sciences,<sup>164</sup> in addition to performing a literature review using search terms in PubMed: (“cerebral vein thrombosis” OR “cerebral venous thrombosis” OR “sinus thrombosis”) AND randomized trial; (“cerebral vein thrombosis” OR “cerebral venous thrombosis” OR “sinus thrombosis”) AND treatment guideline. Secondary sources of data included reference lists of articles reviewed and cohort studies that related treatment to outcomes. A summary algorithm for the diagnosis and management of patients with CVT is provided (Figure 4).

### Setting

Organized care has been defined as collaborative, high-quality, standardized, effective and cost-effective care given by an interdisciplinary team using protocols based on best

practices.<sup>165</sup> According to the Stroke Unit Trialists' Collaboration, the most important components of organized stroke care are assessment by a stroke neurologist, admission to a stroke unit with stroke-directed nursing care, physiotherapy, and occupational therapy.<sup>166–169</sup> Organized care is one of the most effective interventions to reduce mortality and morbidity after acute stroke.<sup>166,167</sup> For example, stroke unit care was associated with a 14% reduction in the odds of death at 1 year (OR 0.86, 95% CI 0.76 to 0.98;  $P=0.02$ ), death or institutionalization (OR 0.82, 95% CI 0.73 to 0.92;  $P<0.001$ ), and death or dependency (OR 0.82, 95% CI 0.73 to 0.92;  $P=0.001$ ). These benefits were independent of age, sex, stroke severity, and stroke subtype.<sup>167,169,170</sup>

CVT is an uncommon but potentially serious and life-threatening cause of stroke. On the basis of findings for stroke unit care in general, management of CVT in a stroke unit is reasonable for the initial management of CVT to optimize care and minimize complications. Additional specialist input as needed to provide therapeutic anticoagulation is appropriate.

### Initial Anticoagulation

There are several rationales for anticoagulation therapy in CVT: To prevent thrombus growth, to facilitate recanalization, and to prevent DVT or PE. Controversy has ensued because cerebral infarction with hemorrhagic transformation or ICH is commonly present at the time of diagnosis of CVT, and it may also complicate treatment. A summary table is provided with data from observational studies and randomized clinical trials<sup>10,84,136,171–181</sup> (Table 5) of CVT.

There are 2 available randomized controlled trials comparing anticoagulant therapy with placebo or open control in patients with CVT confirmed by contrast imaging. Taken together, these trials included only 79 patients. One trial of 20 patients assessed intravenous unfractionated heparin (UFH) using dose adjustment to achieve an activated partial thromboplastin time twice the pretreatment value compared with placebo.<sup>171</sup> This study used a heparin bolus of 3000 U followed by continuous intravenous infusion. The primary outcome was a CVT severity scale at 3 months, which evaluated headache, focal signs, seizures, and level of consciousness. The secondary outcome was ICH. The trial was stopped early after 20 of the planned 60 patients were enrolled because there was a benefit of treatment. Among 10 patients in the heparin group, 8 recovered completely and 2 had mild deficits at 3 months. Among 10 patients in the placebo group, 1 recovered completely, 6 had minor deficits, and 3 died by 3 months. Two patients treated with placebo and none treated with heparin developed ICH. One patient in the placebo group had unconfirmed pulmonary embolus.

The other trial of 59 patients compared subcutaneous nadroparin dosed on the basis of body weight (180 anti-factor Xa units per kilogram daily in 2 divided doses) with placebo for 3 weeks followed by 3 months of oral anticoagulation (without placebo control) in those randomized to nadroparin.<sup>172</sup> The study was blinded during the first 3 weeks and open label thereafter. Primary outcomes were scores for activities of daily living, the Oxford Stroke Handicap Scale, and death. Secondary end points were symptomatic ICH and other major bleeding. At 3 months, 13% of patients in the

**Table 5. Data From Observational Studies and Clinical Trials of CVT That Addressed Anticoagulation Therapy**

First Author	N	Years Recruited	Regimen	F/U Duration	Died, n	Fully Recovered, n*	Disabled, n	ICH	Other Hemorrhage	VTE
Einhaupl <sup>171</sup>	20	1982–4	RCT: 10-UFH 2×PTT 10-Placebo	3 mo	0-UFH 3-Placebo	8-UFH 1-Placebo	2-UFH 6-Placebo	0 2	NR	0-UFH 1-Placebo
De Bruijn <sup>172</sup>	60	1992–6	RCT: 30-Nadroparin 29-Placebo	3 mo	2-UFH 4-Placebo	20-UFH 21-Placebo	8-UFH 4-Placebo	0 0	1-UFH 0-Placebo	0-UFH 1-Placebo
De Bruijn <sup>173</sup>	47	1992–6	RCT as above	18.5 mo	0	16†	3			
Ferro <sup>136</sup>	142	1980–98	112-UFH or AVK‡ 30-None	Hospital stay	9	96§	6 (Rankin ≥3)	4   UFH-AVK 2	2 Systemic 0	NR
Daif <sup>174</sup>	40	1985–94	4-UFH 36-No ACO		1-UFH 3-No ACO	1-UFH 28-None¶	2-UFH 5-None¶	NR	NR	NR
Preter <sup>175</sup>	77	1975–90	62-UFH + AVK 15-None¶	63 mo	Not included	66 Overall	11	0 NR	NR	11 (14%)#
Maqueda <sup>176</sup>	54	1985–2002	30-UFH 48-AVK ≥3 mo	3.5 y	3 (5.6%)	NR	NR	NR	NR	8 (6 off AVK)
Breteau <sup>177</sup>	55	1995–8	UFH + AVK: 6 mo in 56%, entire F/U in 31%	36 mo	7	15 (31%)	23	NR	NR	3
Cakmak <sup>178</sup>	16	1996–2000	UFH/LMWH + AVK	3 mo	0	14	2	NR	NR	NR
Ferro <sup>10</sup> and Giro <sup>84</sup>	624	1998–2001	64% UFH 35% LMWH Most AVK 80% at 6 mo**	16 mo	8.3%	57%	2.2%	36 (6%) de novo 17 ACO; 19 no ACO	NR	4.3%
Stolz <sup>179</sup>	79	1985–2001	63-UFH 2×PTT 5-Lysis 9-LDUFH 2-None 54 had AVK ×1 y	12 mo +	12 in hospital; 2 later (cancer)	57	10	NR	NR	5
Mak <sup>180</sup>	13	1995–1998	12 (3 Heparin)	5–36 mo	1	NR	1	0	NR	1
Brucker <sup>181</sup>	42		42 Heparin + OAC		1	40	1	1	1	1

CVT indicates cerebral venous thrombosis; F/U, follow-up; ICH, new intracerebral hemorrhage during follow-up; VTE, venous thromboembolism; RCT, randomized controlled trial; UFH, unfractionated heparin; PTT, partial thromboplastin time; NR, not reported; AVK, anti-vitamin K; ACO, anticoagulation; LMWH, low-molecular-weight heparin; LDUFH, low-dose unfractionated heparin; and OAC, oral anticoagulation.

\*Definitions for disability vary among studies.

†Recovered completely.

‡Thirty-one of 49 patients with ICH received anticoagulation; 81 of 93 without ICH received anticoagulation.

||One patient was asymptomatic.

§Anticoagulation was associated with a 3.8-fold (95% CI, 1.5–9.6) increased odds of full recovery; not associated with death risk.

¶No comparisons made by treatment status. Nine patients developed recurrent CVT (11.7%), all while not taking anticoagulation therapy.

#Seven had a predisposing condition; it is unknown whether they had stopped anticoagulation therapy.

\*\*A total of 12.7% died or were dependent with early anticoagulation vs 18.3% without early anticoagulation ( $P > 0.05$ ).

nadroparin group had a poor outcome compared with 21% given placebo (treatment difference in favor of nadroparin -7%; 95% CI -26% to 12%). There was no symptomatic ICH in either group (1 nonfatal hemorrhage with nadroparin and 1 fatal unconfirmed pulmonary embolus with placebo). Six patients on active treatment (12%) and 8 control subjects (28%) had full recovery over 3 months.

Meta-analysis of these 2 trials<sup>161</sup> revealed a nonstatistically significant relative risk of death or dependency with anticoagulation (relative risk 0.46, 95% CI 0.16 to 1.31), with a risk

difference in favor of anticoagulation of -13% (95% CI -30% to 3%). The relative risk of death was 0.33 (95% CI 0.08 to 1.21), with a risk difference of -13% (95% CI -27% to 1%).

A third trial randomized 57 women with puerperal CVT confirmed only by CT imaging and excluded those with hemorrhage on CT.<sup>182</sup> Treatment was with subcutaneous heparin 5000 IU every 6 hours, dose adjusted to an activated partial thromboplastin time 1.5 times baseline for at least 30 days after delivery. Outcome assessment was not blinded.



Three patients in the control group either died or had residual paresis compared with none in the heparin group.

In the special situation of CVT with cerebral hemorrhage on presentation, even in the absence of anticoagulation, hemorrhage is associated with adverse outcomes. Highlighting this, in 1 trial of nadroparin, all 6 deaths in the trial overall occurred in the group of 29 patients with hemorrhage on their pretreatment CT scan. None of the deaths were attributed to new or enlarged hemorrhage. These 29 patients were equally divided between treatment groups. Thus, cerebral hemorrhage was strongly associated with mortality but not with cerebral bleeding on treatment. Other studies<sup>171,175</sup> suggested low rates of cerebral hemorrhage after anticoagulation for CVT.

In the special situation of a patient with a major contraindication for anticoagulation (such as recent major hemorrhage), the clinician must balance the risks and benefits of anticoagulation, depending on the clinical situation. In these settings, as for venous thrombosis in general, consultation with an expert in anticoagulation management may be appropriate, and low-intensity anticoagulation may be considered if possible in favor of no anticoagulation until such time as it might be safe to use full-intensity anticoagulation.

### Data From Observational Studies

A number of observational studies, both prospective and retrospective, are available, primarily from single centers.<sup>10,136,175–178</sup> Not all studies reported specifically on outcomes of anticoagulation treatment, because the majority of patients in most studies were treated with intravenous UFH or low-molecular-weight heparin (LMWH) at the time of diagnosis, with eventual use of vitamin K antagonists. Data are summarized in Table 5. Mortality rates were low, typically <10%, often due to the underlying disease (eg, cancer) rather than CVT and rarely due to ICH. The majority of patients fully recovered neurological function, and few became disabled.

In a retrospective study of 102 patients with CVT, 43 had an ICH. Among 27 (63%) who were treated with dose-adjusted intravenous heparin after the ICH, 4 died (15%), and 14 patients (52%) recovered completely. Of the 13 patients who did not receive heparin, mortality was higher (69%) with lower improvement in functional outcomes (only 3 patients completely recovered).<sup>171</sup>

The largest study by far was the ISCVT, which included 624 patients at 89 centers in 21 countries. Nearly all patients were treated with anticoagulation initially, and mortality was 8.3% over 16 months; 79% had complete recovery (modified Rankin scale [mRS] score of 0 to 1), 10.4% had mild to moderate disability (mRS score 2 to 3), and 2.2% remained severely disabled (mRS score 4 to 5).<sup>10</sup> Few studies had sufficient numbers of patients not treated with anticoagulation to adequately address the role of anticoagulation in relation to outcome. Data from observational studies suggest a range of risks for ICH after anticoagulation for CVT from zero to 5.4%.<sup>136,171,181,183</sup>

In conclusion, limited data from randomized controlled clinical trials in combination with observational data on outcomes and bleeding complications of anticoagulation sup-

port a role for anticoagulation in treatment of CVT, regardless of the presence of pretreatment ICH. On the basis of the available data, it is unlikely that researchers will have equipoise on this question, so a new randomized trial may not be feasible. Anticoagulation appears safe and effective. There was consensus in the writing group to support anticoagulation therapy in the management of patients with CVT. If anticoagulation is given, there are no data supporting differences in outcome with the use of UFH in adjusted doses or LMWH in CVT patients. However, in the setting of DVT or PE, a recent systematic review and meta-analysis of 22 studies showed a lower risk of major hemorrhage (1.2% versus 2.1%), thrombotic complications (3.6% versus 5.4%), and death (4.5% versus 6.0%) with LMWH.<sup>184</sup>

### Other Treatments

#### Fibrinolytic Therapy

Although patients with CVT may recover with anticoagulation therapy, 9% to 13% have poor outcomes despite anticoagulation. Anticoagulation alone may not dissolve a large and extensive thrombus, and the clinical condition may worsen even during heparin treatment.<sup>2,6,10,74,84,95,164,170,172,185–191</sup> Incomplete recanalization or persistent thrombosis may explain this phenomenon. Partial or complete recanalization rates for CVT ranged from 47% to 100% with anticoagulation alone.<sup>110,178,192–194</sup>

Unfortunately, most studies reporting partial or complete recanalization at 3 to 6 months have a small sample size. When 4 studies that included 114 CVT patients were combined, partial or complete recanalization at 3 to 6 months was observed in 94 (82.5%).<sup>110,178,192,193</sup> Recanalization rates may be higher for patients who receive thrombolytic therapy.<sup>14</sup> In general, thrombolytic therapy is used if clinical deterioration continues despite anticoagulation or if a patient has elevated intracranial pressure that evolves despite other management approaches.

Many invasive therapeutic procedures have been reported to treat CVT. These include direct catheter chemical thrombolysis and direct mechanical thrombectomy with or without thrombolysis. There are no randomized controlled trials to support these interventions compared with anticoagulation or with each other. Most evidence is based on small case series or anecdotal reports. Here, we review the studied interventions.

#### Direct Catheter Thrombolysis

In direct catheter thrombolysis, a standard microcatheter and microguidewire are delivered to the thrombosed dural sinus through a sheath or guiding catheter from the jugular bulb. Mechanical manipulation of the thrombus with the guidewire increases the amount of clot that might be impacted by the thrombolytic agent, potentially reducing the amount of fibrinolytic agent used.<sup>61,113,131,150,170,188,192,195–205</sup>

In a retrospective multicenter study of CVT in the United States, 27 (15%) of 182 patients received endovascular thrombolysis. Ten patients were receiving concomitant anticoagulation therapy. Recanalization was achieved in 26 patients (96%), 4 developed an intracranial hemorrhage, and 1 patient (4%) died.

A systematic review that included 169 patients with CVT treated with local thrombolysis showed a possible benefit for those with severe CVT, which indicates that fibrinolytics may reduce case fatality in critically ill patients. ICH occurred in 17% of patients after thrombolysis and was associated with clinical worsening in 5%.<sup>206</sup>

### **Mechanical Thrombectomy/Thrombolysis**

#### *Balloon-Assisted Thrombectomy and Thrombolysis*

Despite systemic thrombolysis or mechanical manipulation of the clot with direct fibrinolytic agent delivery, the sinus thrombosis may persist. Balloon-assisted thrombolysis may be more efficient because the inflated balloon may reduce washout of fibrinolytic agents, potentially lessening the dose of fibrinolytic agents required, the occurrence of hemorrhage,<sup>74,207,208</sup> and procedure time. The balloon may be used to perform partial thrombectomy before thrombolysis.<sup>112,209</sup>

#### *Catheter Thrombectomy*

For patients with extensive thrombus that persists despite local administration of a fibrinolytic agent, rheolytic catheter thrombectomy may be considered. One such device is the AngioJet (MEDRAD, Inc, Warrendale, PA), which uses hydrodynamic thrombolytic action occurring at the tip of the catheter via the Venturi effect from high-velocity saline jets. Thrombus is disrupted and directed down the second lumen of the device. Perforation of the venous sinus wall may occur rarely, at a rate that is unknown but reported in the existing small series. It may be avoided by removal of the AngioJet after partial recanalization of the thrombosis and follow-up with additional microcatheter thrombolysis.<sup>187,189,193,198,199,201,202,210,211</sup>

The Merci retrieval device (Concentric Medical, Mountain View, CA) has also been used to remove thrombus in the cerebral venous system. This technique also requires direct catheter access to the venous sinus. The small corkscrew-shaped device is dispensed via the tip of the catheter, advanced into the thrombus, and then slowly pulled back into the catheter with the adherent thrombus. Here again, the device may be used to perform partial recanalization, followed by thrombolysis to avoid damaging the wall or trabeculae of the dural sinus.<sup>195</sup> As mentioned above, the evidence available at the present time is anecdotal.

The Penumbra System (Penumbra, Inc, Alameda, CA) is a new-generation neuroembolectomy device that acts to debulk and aspirate acute clots. It uses a reperfusion catheter that aspirates thrombus while passing a wire-based separator within the catheter to break up the clot and facilitate aspiration. Only anecdotal evidence for its efficacy is available.<sup>212</sup> The risks associated with use of the Penumbra System for cerebral venous thrombosis are likely similar to those seen with the Merci and AngioJet systems.

### **Surgical Considerations**

As endovascular options for management of venous thrombosis have evolved, surgery has played an increasingly limited role. Surgical thrombectomy is needed uncommonly but may be considered if severe neurological or visual deterioration occurs despite maximal medical therapy.<sup>213,214</sup>

In a recent review, among 13 patients with severe CVT who underwent decompressive craniectomy, 11 (84.6%)

achieved a favorable outcome (mRS score  $\leq 3$ ).<sup>215</sup> Decompressive craniotomy may be needed as a life-saving measure if a large venous infarction leads to a significant increase in intracranial pressure. Likewise, large hematomas rarely may need to be considered for surgical evacuation if associated with a progressive and severe neurological deficit.

### **Summary**

The use of these direct intrasinus thrombolytic techniques and mechanical therapies is only supported by case reports and small case series. If clinical deterioration occurs despite use of anticoagulation, or if the patient develops mass effect from a venous infarction or ICH that causes intracranial hypertension resistant to standard therapies, then these interventional techniques may be considered.

### **Aspirin**

There are no controlled trials or observational studies that directly assess the role of aspirin in management of CVT.

### **Steroids**

Steroids may have a role in CVT by decreasing vasogenic edema, but steroids may enhance hypercoagulability. In a matched case-control study among the 624 patients in the ISCVT,<sup>216</sup> 150 patients treated with steroids at the discretion of their healthcare provider were compared with 150 patients not so treated, matched to those treated on the basis of prognostic factors for poor outcome of CVT. Those treated with steroids thus had similar characteristics as control subjects, except they were more likely to have vasculitis. At 6 months, there was a trend toward a higher risk of death or dependence with steroid treatment (OR 1.7, 95% CI 0.9 to 3.3), and this did not differ after the exclusion of those with vasculitis, malignancy, inflammatory disease, and infection. Among those with parenchymal brain lesions on CT/MRI, results were striking, with 4.8-fold increased odds of death or dependence with steroid treatment (95% CI 1.2 to 19.8). Sensitivity analyses that used different analytic approaches yielded similar findings.

### **Antibiotics**

Local (eg, otitis, mastoiditis) and systemic (meningitis, sepsis) infections can be complicated by thrombosis of the adjacent or distant venous sinuses. The management of patients with a suspected infection and CVT should include administration of the appropriate antibiotics and the surgical drainage of infectious sources (ie, subdural empyemas or purulent collections within the paranasal sinuses).

### **Management and Prevention of Early Complications (Hydrocephalus, Intracranial Hypertension, Seizures)**

#### **Seizures**

Seizures are present in 37% of adults, 48% of children, and 71% of newborns who present with CVT.<sup>102,183</sup> No clinical trials have studied either the optimal timing or medication choice for anticonvulsants in CVT. Whether to initiate anticonvulsants in all cases of CVT or await initial seizures before treatment is controversial. Because seizures increase the risk of anoxic damage, anticonvulsant treatment after even a single seizure is reasonable.<sup>217</sup> In the absence of

seizures, the prophylactic use of antiepileptic drugs may be harmful (the risk of side effects may outweigh its benefits).<sup>196,197,209</sup>

A few studies have reported the occurrence and characteristics of patients with seizures accompanying CVT. Among 91 patients, 1 study<sup>218</sup> reported that 32% presented with seizures and 2% developed them during hospitalization; only 9.5% developed late seizures, and seizures were not a predictor of prognosis at 1 year. Early seizures were 3.7-fold more likely (95% CI 1.4 to 9.4) in those with parenchymal lesions on CT/MRI at diagnosis and 7.8-fold more likely (95% CI 0.8 to 74.8) in those with sensory defects. A more recent report from the ISCVT<sup>197</sup> showed 245 (39%) of 624 patients presented with seizures and 43 (6.9%) experienced early seizure within 2 weeks after diagnosis. Besides seizures on presentation, only a supratentorial parenchymal lesion on CT/MRI at diagnosis (present in 58%) was associated with occurrence of early seizures (OR 3.1, 95% CI 1.6 to 9.6). Furthermore, among those with a supratentorial lesion and no presenting seizure, use of antiepileptic drugs was associated with a 70% lower risk of seizures within 2 weeks, although this was not statistically significant (OR 0.3, 95% CI 0.04 to 2.6). On the basis of these findings, the authors suggested the prescription of antiepileptic agents in acute CVT patients with supratentorial lesions who present with seizures.<sup>197</sup>

### Hydrocephalus

The superior sagittal and lateral dural sinuses are the principal sites for CSF absorption by the arachnoid granulations, highly vascular structures that protrude across the walls of the sinuses into the subarachnoid space and drain into the venous system. In CVT, the function of the arachnoid granulations may be impaired, potentially resulting in failure of CSF absorption and communicating hydrocephalus (6.6%).<sup>14,198</sup>

Obstructive hydrocephalus is a less common complication of CVT and results from hemorrhage into the ventricular system. This is typically associated with thrombosis that involves the internal cerebral veins and may be associated with thalamic hemorrhage. This syndrome is well described in term neonates but occurs at all ages.<sup>201,205</sup> Neurosurgical evacuation of CSF with ventriculostomy, or in persistent cases, ventriculoperitoneal shunt, is necessary. The brain is under increased venous pressure, and tissue perfusion is at increased risk compared with other situations with obstructive hydrocephalus. Therefore, close monitoring and neurosurgical consultation are important, because intervention may be required at lesser severities of ventricular enlargement.

### Intracranial Hypertension

Up to 40% of patients with CVT present with isolated intracranial hypertension.<sup>183</sup> This is characterized by diffuse brain edema, sometimes seen as slit ventricles on CT scanning. Clinical features include progressive headache, papilledema, and third or sixth nerve palsies. Intracranial hypertension is primarily caused by venous outflow obstruction and tissue congestion compounded by CSF malabsorption.

No randomized trials are available to clarify the optimal treatment; however, rational management of intracranial hypertension includes a combination of treatment approaches. First, measures to reduce the thrombotic occlusion of venous

outflow, such as anticoagulation and possibly thrombolytic treatment, may result in resolution of intracranial hypertension. Second, reduction of increased intracranial pressure can be accomplished immediately by lumbar puncture with removal of CSF until a normal closing pressure is achieved. Unfortunately, lumbar puncture requires temporary cessation of anticoagulants, with an attendant risk of thrombus propagation. Despite the lack of randomized clinical trials, acetazolamide is a commonly used therapeutic alternative for the treatment of intracranial hypertension with CVT.<sup>139</sup> It may have a limited role in the acute management of intracranial hypertension for patients with CVT. Acetazolamide, a carbonic anhydrase inhibitor, is a weak diuretic and decreases production of CSF. Although used occasionally, corticosteroids are not efficacious<sup>216</sup> and carry risks of associated hyperglycemia and high lactate, which are deleterious to an ischemic brain. Serial lumbar punctures may be necessary when hypertension is persistent. In refractory cases, a lumbo-peritoneal shunt may be required.<sup>199</sup> Because prolonged pressure on the optic nerves can result in permanent blindness, it is of paramount importance to closely monitor visual fields and the severity of papilledema during the period of increased pressure. Ophthalmologic consultation is helpful for this. Although rarely required, optic nerve fenestration is a treatment option to halt progressive visual loss.

Decompressive craniectomy has been used in patients with malignant arterial stroke to treat elevated intracranial pressure unresponsive to conventional treatment. In a pooled analysis of randomized trials, surgical decompression within 48 hours of stroke onset reduced case fatality and improved functional outcome.<sup>204</sup> Limited evidence is available on the role of decompressive craniectomy in CVT with either brain edema, venous infarction, neurological deterioration, or impending cerebral herniation.<sup>200,202,203</sup> A disadvantage of craniectomy is that it precludes anticoagulation for the immediate postoperative period.

### Recommendations

1. **Patients with CVT and a suspected bacterial infection should receive appropriate antibiotics and surgical drainage of purulent collections of infectious sources associated with CVT when appropriate (Class I; Level of Evidence C).**
2. **In patients with CVT and increased intracranial pressure, monitoring for progressive visual loss is recommended, and when this is observed, increased intracranial pressure should be treated urgently (Class I; Level of Evidence C).**
3. **In patients with CVT and a single seizure with parenchymal lesions, early initiation of antiepileptic drugs for a defined duration is recommended to prevent further seizures<sup>218</sup> (Class I; Level of Evidence B).**
4. **In patients with CVT and a single seizure without parenchymal lesions, early initiation of antiepileptic drugs for a defined duration is probably recommended to prevent further seizures (Class IIa; Level of Evidence C).**
5. **In the absence of seizures, the routine use of antiepileptic drugs in patients with CVT is not recommended (Class III; Level of Evidence C).**

6. For patients with CVT, initial anticoagulation with adjusted-dose UFH or weight-based LMWH in full anticoagulant doses is reasonable, followed by vitamin K antagonists, regardless of the presence of ICH<sup>161,171,172,175,181,183</sup> (Class IIa; Level of Evidence B). (For further details, refer to “Acute Management and Treatment of CVT: Initial Anticoagulation.”)
7. Admission to a stroke unit is reasonable for treatment and for prevention of clinical complications of patients with CVT (Class IIa; Level of Evidence C).
8. In patients with CVT and increased intracranial pressure, it is reasonable to initiate treatment with acetazolamide. Other therapies (lumbar puncture, optic nerve decompression, or shunts) can be effective if there is progressive visual loss. (Class IIa; Level of Evidence C).
9. Endovascular intervention may be considered if deterioration occurs despite intensive anticoagulation treatment (Class IIb; Level of Evidence C).
10. In patients with neurological deterioration due to severe mass effect or intracranial hemorrhage causing intractable intracranial hypertension, decompressive hemicraniectomy may be considered (Class IIb; Level of Evidence C).
11. For patients with CVT, steroid medications are not recommended, even in the presence of parenchymal brain lesions on CT/MRI, unless needed for another underlying disease<sup>216</sup> (Class III; Level of Evidence B).

## Long-Term Management and Recurrence of CVT

### Risk of Recurrence With and Without Anticoagulation

Prevention strategies focus on preventing recurrence of CVT or other VTE in those CVT patients at high risk of these outcomes. There are no available risk stratification schemes in CVT, but patients with certain thrombophilic conditions or medical conditions, such as cancer, might be considered high risk. There are no randomized clinical trials of long-term prevention of first or recurrent CVT. Overall, there is approximately a 6.5% annual risk of any type of recurrent thrombosis.<sup>10,117</sup>

Because there are no secondary prevention trials of anticoagulation in adults with CVT, evaluation of prevention strategies can only be performed with observational studies that evaluate recurrence of CVT or VTE with or without ongoing anticoagulation. In a cohort of 154 patients treated at Mayo Clinic between 1978 and 2001, 56 patients initially received both heparin and warfarin, 12 received heparin only, and 21 received warfarin only.<sup>61</sup> Seventy-seven (50%) were treated with warfarin for an average of 9 months, with 25 committed to lifelong therapy.<sup>61</sup> During 36 months of follow-up (464 patient-years), there were 23 recurrent VTEs in 20 patients (13%), the majority in the first year. Ten patients had recurrent CVT (2.2 per 100 patient-years), and 11 had DVT or PE (2.8 per 100 patient-years). Nine of the recurrent events occurred while the patients were taking warfarin. After 8 years of follow-up, there was no impact of warfarin on survival or recurrence-free survival.<sup>61</sup>

In a cohort of 54 CVT patients treated consecutively at University Hospital Gasthuisberg, Leuven, Belgium, 8 (14.8%) had a recurrence of VTE (7 with DVT or PE, 1 with CVT and mesenteric vein thrombosis) over a median of 2.5

years of follow-up (4.5 per 100 patient-years). Median time to recurrence was 2.5 months (range 2 weeks to 4 years). Only 2 of these 8 patients were taking anticoagulants at the time of recurrence, 1 with an international normalized ratio (INR) of 1.6 and the other with an INR of 2.1. Among the 6 patients with recurrent VTE who were not taking anticoagulants, recurrence occurred between 2 weeks and 10 months after the index event. Those with recurrence more often had a thrombophilic disorder, had a history of DVT, and had not received oral anticoagulation because of perceived contraindications.<sup>176</sup>

In the ISCVT study, among 624 patients with CVT, there were 14 (2.2%) recurrent CVTs and 27 (4.3%) other thrombotic events (16 DVT, 3 PE, 2 ischemic stroke, 2 transient ischemic attack, and 4 acute limb ischemia) over a mean follow-up of 16 months.<sup>10</sup> Seventeen (41.5%) of the 41 patients with recurrent or other thrombotic events were receiving anticoagulants, but the type of anticoagulation and the number who were receiving therapeutic doses of anticoagulation were unknown.<sup>10</sup> It was not reported whether anticoagulation was given long-term and whether recurrent events differed based on its use.

The Cerebral Venous Thrombosis Portuguese Collaborative Study Group (VENOPORT) evaluated outcomes for 142 CVT patients, of whom 51 were retrospectively enrolled and 91 were prospectively enrolled. There were 2 (2%) recurrent CVTs and 10 (8%) other arterial or venous thrombotic events (maximum 16 years of follow-up for the retrospective cases and 12 months of follow-up for prospective cases).<sup>117</sup> For the prospectively followed cases, the incident risk of a thrombotic event was 4% per year (5 thrombotic events in 4 patients: 2 DVTs, 1 PE, 1 ischemic stroke, and 1 acute limb ischemia). Three of these events occurred with anticoagulation use, although the INR levels were unknown at the time of the event. In addition, all of these events occurred within 12 months of the index CVT.<sup>117</sup>

A cohort of 77 CVT patients diagnosed in France between 1975 and 1990 was followed up for 63 months.<sup>175</sup> Nine (11.7%) had a recurrence of CVT, 8 during the first 12 months, and none were receiving anticoagulation at the time of recurrence. Eleven patients (14.3%) had other thrombotic events, including retinal vein thrombosis, PE, and arterial thromboses.<sup>175</sup> Use of anticoagulation at the time of recurrent thromboses that were not CVTs was not reported.

More recently, 145 patients with a first CVT were followed up for a median of 6 years after discontinuation of anticoagulation therapy. CVT recurred in 5 patients (3%), and other manifestations of VTE (defined as DVT of the lower limbs or PE) were seen in 10 additional patients (7%). The recurrence rate accounted for 3.4% of all VTEs in the first 16 months (or 2.03 per 100 person-years; 95% CI 1.16 to 3.14) and 1.3% of CVTs in the first 16 months (or 0.53 per 100 person-years; 95% CI 0.16 to 1.10). Approximately half of the recurrences occurred within the first year after discontinuation of anticoagulant therapy. Mild thrombophilia abnormalities were not associated with recurrent CVT, but severe thrombophilia showed an increased risk of DVT or PE.<sup>210</sup> In summary, the prevalence of CVT recurrence was similar in the Italian and ISCVT studies (1.3% and 2.2%, respectively<sup>10,209</sup>) at the 16-month follow-up.

The overall risk of recurrence of any thrombotic event (CVT or systemic) after a CVT is  $\approx 6.5\%$ . The risk of other manifestations of VTE after CVT ranges from 3.4%<sup>209</sup> to 4.3%<sup>10</sup> on the basis of the largest studies of this medical condition.<sup>10</sup> Patients with severe thrombophilia have an increased risk of VTE.

### **Secondary Prevention of CVT and Other VTE Events**

DVT/PE and CVT share some similarities. The chronic and transient risk factors appear to be similar, although women are more likely to have CVT,<sup>61</sup> and selected thrombophilia subtypes may differ between CVT and DVT/PE.<sup>211</sup> In the ISCVT cohort, the overall rate of recurrent CVT or other VTE recurrence was 4.1 per 100 person-years, with male sex and polycythemia/thrombocytosis being the only independent predictors found. The same study reported a steady increase in the cumulative risk of thrombotic recurrences not influenced by the duration of anticoagulation, which emphasizes the need for a clinical trial to assess the efficacy and safety of short versus extended anticoagulant therapy.<sup>219</sup> Given that systemic VTE after CVT is more common than recurrent CVT, one may reasonably adopt the VTE guidelines for prevention of both new VTE and recurrent CVT.<sup>219,220</sup> However, each individual patient should undergo risk assessment (see “Thrombophilias and Risk Stratification for Long-Term Management” below), and the patient’s risk level and preferences regarding long-term anticoagulation treatment, the risk of bleeding, and the risk of thrombosis without anticoagulation should then be considered.<sup>220</sup>

### **Thrombophilias and Risk Stratification for Long-Term Management**

Thrombophilias may be hereditary or acquired, and hereditary thrombophilias have been stratified as mild or severe on the basis of the risk of recurrence in very large family cohorts.<sup>221</sup> Among VTE patients, the hereditary thrombophilias with the highest cumulative recurrence rates for VTE in the absence of ongoing anticoagulation have been deficiencies of antithrombin, protein C, and protein S, with a 19% recurrence at 2 years, 40% at 5 years, and 55% at 10 years. Homozygous prothrombin G20210A; homozygous factor V Leiden; deficiencies of protein C, protein S, or antithrombin; combined thrombophilia defects; and antiphospholipid syndrome are categorized as severe.

Interestingly, the more common hereditary thrombophilias, such as heterozygous factor V Leiden and prothrombin G20210A or elevated factor VIII, have a much lower risk of recurrence (7% at 2 years, 11% at 5 years, and 25% at 10 years) and could be categorized as mild.<sup>221</sup> Hyperhomocysteinemia, a common hereditary or acquired risk factor for VTE, was not significantly associated with a high risk of recurrence.<sup>10,28</sup> In addition, the annual incidence and the risk of recurrence increased markedly in those with combined thrombophilic defects, described as double heterozygous/homozygous.<sup>221</sup>

There are several important points regarding the hereditary thrombophilia data described above. First, the familial nature of these deficiencies of protein C, S, or antithrombin was clearly established, which distinguishes these patients from those with sporadic or acquired abnormalities. Second, testing for deficiencies of protein C, S, and antithrombin must be

performed at least 6 weeks after a thrombotic event and then confirmed with repeat testing and family studies. In addition, protein C and S functional activity and antithrombin levels are difficult to interpret during treatment with warfarin. Therefore, testing for these conditions is generally indicated 2 to 4 weeks after completion of anticoagulation.<sup>222,223</sup> Lastly, clearly established deficiencies of proteins C, S, and antithrombin are relatively uncommon.

Antiphospholipid antibody syndrome is an acquired thrombophilia associated with specific laboratory criteria (lupus anticoagulant, anticardiolipin antibody, and anti- $\beta 2$ -glycoprotein I) and a history of a venous or arterial event or fetal loss.<sup>224</sup> Caution must be taken when the results of antiphospholipid antibody testing are interpreted. A normal result may occur at the time of the clinical presentation, which rules out antiphospholipid antibody syndrome. On the other hand, abnormal tests may occur transiently due to the disease process, infection, certain medications (antibiotics, cocaine, hydralazine, procainamide, quinine, and others), or unknown causes. Approximately 5% of the general population at any given time has evidence of abnormal tests, and these mainly have no clinical consequence.<sup>224,225</sup>

A diagnosis of antiphospholipid syndrome requires abnormal laboratory testing on 2 or more occasions at least 12 weeks apart.<sup>226</sup> Patients diagnosed with antiphospholipid syndrome have an increased risk of recurrent thrombotic events; however, test results cannot predict the likelihood of complications, their type, or their severity in a particular patient.

Although there are no prospective studies that report recurrence rates for CVT specifically, the high risk of recurrent VTE with this disorder meets the definition of severe thrombophilia. The Duration of Anticoagulation Study Group reported a 29% recurrence of VTE in patients with anticardiolipin antibodies versus 14% in those without them ( $P=0.001$ ) over a 4-year period, and the risk increased with the titer of the antibodies.<sup>227</sup> In a randomized controlled trial of warfarin for 3 months versus extended treatment for 24 months after first-ever idiopathic DVT or PE, the presence of antiphospholipid antibodies was associated with a 4-fold increased risk of recurrence (hazard ratio [HR] 4.0, 95% CI 1.2 to 13), and the presence of a lupus anticoagulant was associated with a 7-fold increased risk (HR 6.8, 95% CI 1.5 to 31) in the placebo group.<sup>228</sup> The current recommendations for VTE patients call for indefinite anticoagulation (adjusted-dose warfarin INR 2.0 to 3.0 or heparin) for patients with antiphospholipid syndrome.<sup>220</sup>

### **Other Tests That Might Define Risk of Recurrent CVT or VTE After CVT**

In patients with DVT or PE, increasing evidence suggests there is clinical utility to D-dimer measurement when used to define risk of recurrent VTE.<sup>224,229,230</sup> For example, in a randomized controlled trial ( $n=608$ ), patients with an abnormal D-dimer level 1 month after the discontinuation of anticoagulation had a significant incidence of recurrent VTE (15% versus 2.9%), which was reduced by the resumption of anticoagulation (compared with those not receiving vitamin K antagonists,  $P=0.02$ ).<sup>231</sup> During 1.4 years of follow-up, 120 subjects with an abnormal D-dimer level were randomized to no anticoagulation, and 18 (15%) in this group

developed a recurrent VTE. Of the 103 patients with abnormal D-dimer randomized to resume anticoagulation, only 3 (2.9%) had a recurrent VTE.<sup>231</sup> Although the study was randomized, it was unblinded, and D-dimer levels were only obtained once. In addition, there were no subjects with CVT and no similar studies in CVT patients. Although the clinical utility of D-dimer for longer-term anticoagulation for VTE secondary prevention appears promising, the lack of standardization of D-dimer assays may limit their clinical applicability and reliability.<sup>232</sup>

### Recommendations

1. **Testing for prothrombotic conditions, including protein C, protein S, antithrombin deficiency, antiphospholipid syndrome, prothrombin G20210A mutation, and factor V Leiden, can be beneficial for the management of patients with CVT. Testing for protein C, protein S, and antithrombin deficiency is generally indicated 2 to 4 weeks after completion of anticoagulation. There is a very limited value of testing in the acute setting or in patients taking warfarin.**<sup>222–226</sup> (*Class IIa; Level of Evidence B*).
2. **In patients with provoked CVT (associated with a transient risk factor), vitamin K antagonists may be continued for 3 to 6 months, with a target INR of 2.0 to 3.0 (Table 3)** (*Class IIb; Level of Evidence C*).
3. **In patients with unprovoked CVT, vitamin K antagonists may be continued for 6 to 12 months, with a target INR of 2.0 to 3.0** (*Class IIb; Level of Evidence C*).
4. **For patients with recurrent CVT, VTE after CVT, or first CVT with severe thrombophilia (ie, homozygous prothrombin G20210A; homozygous factor V Leiden; deficiencies of protein C, protein S, or antithrombin; combined thrombophilia defects; or antiphospholipid syndrome), indefinite anticoagulation may be considered, with a target INR of 2.0 to 3.0** (*Class IIb; Level of Evidence C*).
5. **Consultation with a physician with expertise in thrombosis may be considered to assist in the prothrombotic testing and care of patients with CVT** (*Class IIb; Level of Evidence C*).

### Management of Late Complications (Other Than Recurrent VTE)

#### Headache

Headache is a common complaint during the follow-up of CVT patients, occurring in ≈50% of patients.<sup>193,205</sup> In general, headaches are primary and not related to CVT. In the Lille study,<sup>177</sup> 53% of patients had residual headache, 29% fulfilled criteria for migraine, and 27% had headache of the tension type. In VENOPORT,<sup>205</sup> 55% of patients reported headaches during the follow-up, and these were mild to moderate in 45%. In a series of 17 patients presenting with headache as the only neurological sign of CVT, several patients had headaches at 3 months, which comprised migraine attacks similar to those that occurred previously (4), tension type (2), and new onset of migraine with aura (2).<sup>64</sup> At follow-up, severe headaches that required bed rest or hospital admission were reported in 14% of patients in the ISCVT<sup>10</sup> and 11% in VENOPORT.<sup>117</sup> In patients with persistent or severe headaches, appropriate investigations should be completed to rule out recurrent CVT. Occasionally, MRV may show

stenosis of a previously occluded sinus, but the clinical significance of this is unclear. Headache during follow-up is more common among patients who present acutely as having isolated intracranial hypertension. In these patients, if headache persists and MRI is normal, lumbar puncture may be needed to exclude elevated intracranial pressure.

#### Seizures

Focal or generalized post-CVT seizures can be divided into early or remote (occurring >2 weeks after diagnosis) seizures.<sup>10,197</sup> On the basis of case series, remote seizures affect 5% to 32% of patients. Most of these seizures occur in the first year of follow-up.<sup>175,218</sup> In ISCVT, 11% of the patients experienced remote seizures (36 patients by 6 months, 55 by 1 year, and 66 by 2 years). Risk factors for remote seizures were hemorrhagic lesion on admission CT/MRI (HR 2.62, 95% CI 1.52 to 4.52), early seizure (HR 2.42, 95% CI 1.38 to 4.22), and paresis (HR 2.22, 95% CI 1.33 to 3.69). Five percent of the patients had post-CVT epilepsy (>1 remote seizure). Post-CVT epilepsy was also associated with hemorrhagic lesion on admission CT/MRI (OR 6.76, 95% CI 2.26 to 20.41), early seizure (OR 3.99, 95% CI 1.16 to 11.0), and paresis (OR 2.75, 95% CI 1.33 to 6.54).<sup>234</sup> Initiation of antiepileptic drugs for a defined duration is recommended to prevent further seizures in patients with CVT and parenchymal lesions who present with a single seizure. Recommendations covering different scenarios are provided in the section on the “Management and Prevention of Early Complications.”

#### Visual Loss

Severe visual loss due to CVT rarely occurs (2% to 4%).<sup>55,193,235</sup> Papilledema can cause transient visual impairment, and if prolonged, optic atrophy and blindness may ensue. Visual loss is often insidious, with progressive constriction of the visual fields and relative sparing of central visual acuity. Visual deficits are more common in patients with papilledema and those who present with increased intracranial pressure. Delayed diagnosis is associated with an increased risk of later visual deficit. Patients with papilledema or visual complaints should have a complete neuro-ophthalmological study, including visual acuity and formal visual field testing.

#### Dural Arteriovenous Fistula

Thrombosis of the cavernous, lateral, or sagittal sinus can later induce a dural arteriovenous fistula.<sup>236</sup> A pial fistula can also follow a cortical vein thrombosis. The relationship between the 2 entities is rather complex, because (1) dural fistulas can be a late complication of persistent dural sinus occlusion with increased venous pressure, (2) the fistula can close and cure if the sinus recanalizes, and (3) a preexisting fistula can be the underlying cause of CVT. The exact frequency of dural fistula after CVT is not known because there are no cohort studies with long-term angiographic investigation. The incidence of dural arteriovenous fistula was low in cohort studies without systematic angiographic follow-up (1% to 3%).<sup>55,94,201,205,237</sup> A cerebral angiogram may help identify the presence of a dural arteriovenous fistula.

### Recommendation

- 1. In patients with a history of CVT who complain of new, persisting, or severe headache, evaluation for CVT recurrence and intracranial hypertension should be considered (Class I; Level of Evidence C).**

## CVT in Special Populations

### CVT During Pregnancy

Pregnancy induces changes in the coagulation system that persist into the puerperium and result in a hypercoagulable state, which increases the risk of CVT. Incidence estimates for CVT during pregnancy and the puerperium range from 1 in 2500 deliveries to 1 in 10 000 deliveries in Western countries, and ORs range from 1.3 to 13.<sup>238–240</sup> The greatest risk periods for CVT include the third trimester and the first 4 postpartum weeks.<sup>240</sup> Up to 73% of CVT in women occurs during the puerperium.<sup>241</sup> Cesarean delivery appears to be associated with a higher risk of CVT after adjustment for age, vascular risk factors, presence of infections, hospital type, and location (OR 3.10, 95% CI 2.26 to 4.24).<sup>35</sup>

Vitamin K antagonists, including warfarin, are associated with fetal embryopathy and bleeding in the fetus and neonate and thus are generally believed to be contraindicated in pregnancy. Therefore, anticoagulation for CVT during pregnancy and early in the puerperium consists of LMWH in the majority of women.<sup>220</sup>

In contrast to UFH, LMWH is not associated with teratogenicity or increased risk of fetal bleeding. The American College of Chest Physicians guidelines for antithrombosis address prevention and treatment of DVT and pulmonary embolus in pregnancy and the puerperium, recommending LMWH over UFH (recommendation 4.2.1).<sup>241a</sup> They recommend that treatment be continued throughout pregnancy and for at least 6 weeks postpartum (for a total minimum duration of treatment of 6 months). Although these recommendations are directed to systemic venous thrombosis, it is logical to apply them to CVT for several reasons. First, safety in terms of teratogenicity and fetal/newborn/maternal bleeding complications should be similar, and second, the recommendations are concordant with treatment of non-pregnancy-associated CVT. In a retrospective cohort study of 37 high-risk pregnancies, once-daily tinzaparin was studied for the prevention of initial or recurrent cerebral thrombosis. During treatment, no systemic venous thrombosis occurred; however, 1 parietal infarct and 1 postpartum CVT were documented.<sup>242</sup> As in nonpregnant women, fibrinolytic therapy is reserved for patients with deterioration despite systemic anticoagulation, and its use has been reported during pregnancy.<sup>243</sup>

### Future Pregnancies and Recurrence

Patients with previous VTE are at increased risk of further venous thrombotic events compared with healthy individuals.<sup>244,245</sup> Similarly, women with a history of VTE appear to have an increased risk of thrombotic events (ie, DVT, PE) in future pregnancies.<sup>57</sup> Pregnancy, and in particular puerperium, are known risk factors for CVT. Six studies investigated the outcome and complications of pregnancy in women who had CVT,<sup>10,117,175,246–248</sup> with a total of 855 women

under observation, of whom 83 became pregnant (101 pregnancies) after their CVT.

These studies found that the risk of complications during future pregnancies was low. In fact, 88% of the pregnancies ended in a normal birth, the remainder being terminated prematurely by voluntary or spontaneous abortion. There was only 1 case of recurrent CVT and 2 cases of DVT; however, a high proportion of spontaneous abortion was noted.

On the basis of the available evidence, CVT is not a contraindication for future pregnancies. Considering the additional risk that pregnancy confers to women with a history of CVT, prophylaxis with LMWH during future pregnancies and the postpartum period can be beneficial.

### Recommendations

- 1. For women with CVT during pregnancy, LMWH in full anticoagulant doses should be continued throughout pregnancy, and LMWH or vitamin K antagonist with a target INR of 2.0 to 3.0 should be continued for at least 6 weeks postpartum (for a total minimum duration of therapy of 6 months) (Class I; Level of Evidence C).**
- 2. It is reasonable to advise women with a history of CVT that future pregnancy is not contraindicated. Further investigations regarding the underlying cause and a formal consultation with a hematologist and/or maternal fetal medicine specialist are reasonable.<sup>10,117,175,246–248</sup> (Class IIa; Level of Evidence B).**
- 3. It is reasonable to treat acute CVT during pregnancy with full-dose LMWH rather than UFH (Class IIa; Level of Evidence C).**
- 4. For women with a history of CVT, prophylaxis with LMWH during future pregnancies and the postpartum period is probably recommended (Class IIa; Level of Evidence C).**

## CVT in the Pediatric Population

The incidence of pediatric CVT is 0.67 per 100 000 children per year.<sup>91</sup> When neonates are excluded, the reported incidence is 0.34 per 100 000 children per year.<sup>249</sup> Neonates present with seizures or lethargy, whereas older infants and children (similar to adults) usually present with seizures, altered levels of consciousness, increasing headache with papilledema, isolated intracranial hypertension, or focal neurological deficits.

### Risk Factors

Risk factors for pediatric CVT are age related. Neonates constitute 43% of pediatric patients with CVT.<sup>91</sup> There are several likely reasons for their increased risk. First, considerable mechanical forces are exerted on the infant's head during birth that result in molding of the skull bones along the suture lines. This results in mechanical distortion of and damage to the underlying dural venous sinuses and thrombosis. The neonate also has an increased thrombotic tendency.<sup>250</sup> First, there is a transplacental transfer of circulating maternal antiphospholipids to the fetus, which can persist into the newborn period.<sup>251</sup> Second, neonates have reduced levels of circulating anticoagulant proteins, including proteins C and S and antithrombin, and higher hematocrit relative to adults. Furthermore, hemoconcentration occurs with the normal fluid loss and relative dehydration of the neonate during the first week of postnatal life.

Multiple risk factors are present in more than half of neonates with CVT.<sup>252</sup> Additional complications of gestation and labor and delivery increase the risk of CVT. Maternal preeclampsia/eclampsia is a reported risk factor for neonatal CVT.<sup>253</sup> Neonatal diseases including head and neck infections, meningitis, dehydration secondary to feeding difficulties or gastroenteritis, and congenital heart disease also cause CVT.<sup>91</sup>

A recent meta-analysis of observational studies estimated the impact of thrombophilia on the incident risk of arterial ischemic stroke and CVT. The reported magnitude of association was as follows: Antithrombin deficiency, OR 7.1 (95% CI 2.4 to 22.4); protein C deficiency, OR 8.8 (95% CI 4.5 to 17.0); protein S deficiency, OR 3.2 (95% CI 1.2 to 8.4); factor V G1691A, OR 3.3 (95% CI 2.6 to 4.1); factor II G20210A, OR 2.4 (95% CI 1.7 to 3.5); methylenetetrahydrofolate reductase C677T (arterial ischemic stroke), OR 1.58 (95% CI 1.2 to 2.1); antiphospholipid antibodies (arterial ischemic stroke), OR 7.0 (95% CI 3.7 to 13.1); elevated lipoprotein(a), OR 6.3 (95% CI 4.5 to 8.7); and combined thrombophilias, OR 11.9 (95% CI 5.9 to 23.7). The authors also concluded that further studies are needed to determine the impact of thrombophilias on outcome and recurrence risk.<sup>250</sup>

In older children and adolescents, systemic lupus erythematosus, nephrotic syndrome, leukemia or lymphoma with L-asparaginase treatment, and trauma are reported causes of CVT.<sup>102,245</sup> Iron deficiency anemia is an established risk factor for CVT.<sup>254</sup> Prothrombotic disorders ranged from 33% to 66% of neonatal and pediatric CVTs and are frequently present when there are other risk factors for CVT.<sup>102</sup>

### Radiographic Diagnosis

As in adults, a high index of suspicion for CVT and specific venous imaging are required make a diagnosis. This is especially true for neonates, who have nonspecific presentations that consist solely of seizures in the majority. The neuroimaging findings of CVT are similar in children and adults. In neonates, 2-dimensional TOF MRV has several pitfalls, including a focal area of absent flow where the occipital bone compresses the posterior superior sagittal sinus in the supine position. This is present in up to 14% of neonates without CVT.<sup>255,256</sup> Therefore, CTV is frequently required to confirm the presence of CVT suggested by MRV. In neonates, transfontanelar Doppler ultrasound can suggest CVT by demonstrating an absence of flow from an occlusive thrombus; however, in partially occlusive thrombosis, this technique may not be as reliable.<sup>257</sup>

Parenchymal lesions are more likely hemorrhagic in neonates than in children.<sup>102</sup> Intracranial hemorrhage in neonates frequently includes subtentorial subdural hemorrhage. Term neonates with intraventricular hemorrhage have CVT as the cause in 34% of cases, frequently in association with thalamic hemorrhage.<sup>205</sup>

### Outcome

CVT is associated with a significant frequency of adverse outcomes in neonates and older infants and children. In neonates, long-term follow-up is required to ascertain the outcomes, because deficits may only become evident with brain maturation over many years. Among neonates with CVT, neurological deficits are observed in 28%<sup>258</sup> to 83%.<sup>102,245,253,259</sup> Differences among studies may relate to treatment protocols: In 1 study of 39 neonates with CVT, neurological deficits were reported in 83%,

and only 10% of neonates received anticoagulation. In contrast, in a Canadian Registry that included 160 children with CVT, venous infarction occurred in 42%, and 8% died. Additional outcomes included seizures in 20% and symptomatic recurrent thrombosis in 19 children (13%; CVT in 12 and extracerebral thrombosis in the remaining 7 children). Among the 63 neonates with CVT, neurological deficits were seen in only 34%, anticoagulation was used in 36%, and mortality among neonates was 7%.<sup>102</sup> In CVT occurring beyond the newborn period, neurological deficits are reported in 17% to 46% of cases.<sup>43,175,185,260,261</sup>

One study showed that 18% of children with CVT had residual visual impairment on long-term follow-up. Other studies reported similar findings in children and adults with CVT.<sup>237,235,262</sup>

### Management of CVT in the Pediatric Population

Consideration of endovascular treatment for neonates and children with CVT is driven by the high rates of adverse outcomes. No randomized clinical trials have been conducted in pediatric CVT. Therefore, treatment practices have been extrapolated primarily from adult studies.

In children, and increasingly in neonates, the mainstay of CVT treatment is anticoagulation, including LMWH, UFH, and warfarin. Individual and regional practices vary widely in pediatric CVT and particularly in neonatal CVT. Seizures were observed in >50% of the pediatric population with CVT.<sup>102</sup> Given the higher frequency of epileptic seizures in children, continuous electroencephalography monitoring may be considered for unconscious or mechanically ventilated children.

### Primary Evidence

Despite the absence of randomized trials, increasing evidence from case series and large observational studies supports the efficacy of anticoagulation in children or neonates with CVT.<sup>72,179,201,236,263</sup> In the Canadian Pediatric Ischemic Stroke Registry, 85 of 160 children with CVT at 16 Canadian children's hospitals received anticoagulation (25 neonates and 60 non-neonates). There were no fatal or severe complications reported; however, follow-up was not systematic.<sup>102</sup>

In a European multicenter study among 396 pediatric patients (75 neonates) with CVT, 250 (63%) received acute anticoagulation. Twenty-two (6%) had recurrent VTE (13 cerebral; 3%) after a median of 6 months of follow-up. In the multivariable survival analysis, nonadministration of an anticoagulant before relapse (HR 11.2, 95% CI 3.4 to 37.0;  $P < 0.0001$ ), persistent occlusion on repeat venous imaging (HR 4.1, 95% CI 1.1 to 14.8;  $P = 0.032$ ), and heterozygosity for the prothrombin G20210A mutation (HR 4.3, 95% CI 1.1 to 16.2;  $P = 0.034$ ) were independently associated with recurrent VTE. Of note, there was no significant difference in recurrence based on medical conditions such as cancers (acute lymphoblastic leukemia, lymphoma, or brain tumor), type I diabetes mellitus, nephrotic syndrome, infectious diseases, or heparin-induced thrombocytopenia. The number of CVT cases needed to screen to detect at least 1 prothrombin G20210A heterozygote was 16. The number needed to treat for 1 year with anticoagulation to prevent 1 recurrent VTE was 32 for the entire group. The number needed to treat



was 3 for those with prothrombin G20210A who were older than 2 years of age at diagnosis of CVT.<sup>245</sup>

A recently published case series from the Netherlands studied anticoagulation use in neonates with CVT, intraventricular hemorrhage, or thalamic hemorrhage.<sup>201</sup> Among the 10 neonates, 1 infant died before therapy could be initiated, and 2 were born before typical use of LMWH therapy. The remaining 7 neonates received 3 months of LMWH (dalteparin) with a target anti-Xa level of 0.5 to 1.0 U/mL. There were no increased or new hemorrhages during treatment. Another pediatric CVT study that included 42 children reported safety and improved outcomes with anticoagulation even in the presence of ICH.<sup>187</sup> Finally, in a prospective single-center study of protocol-based anticoagulation therapy among 162 pediatric patients, approximately half received anticoagulation at diagnosis, including 35% of neonates and 71% of children. Hemorrhagic complications were rare (6%); all were nonfatal and were associated with a favorable clinical outcome in the majority. Propagation of CVT thrombus was observed in more than one quarter of neonates and more than one third of children not treated with anticoagulation.<sup>264</sup> Further studies on optimal dosing of anticoagulation with stratification by cerebral hemorrhage at the time of the diagnosis are in the planning stage through the International Pediatric Stroke Study.<sup>265,266</sup>

#### Published Pediatric Stroke Guidelines

In the past 5 years, 3 sets of guidelines addressing treatment of pediatric CVT were published.<sup>267–269</sup> All 3 guidelines recommended use of anticoagulation with LMWH, UFH, and/or warfarin for 3 to 6 months in children beyond the newborn period, even in the presence of intracranial hemorrhage.

By contrast, recommendations regarding anticoagulation for neonatal CVT have been discordant. Of the 3 published guidelines, 1 did not address neonatal CVT,<sup>268</sup> 1 recommended acute anticoagulation,<sup>269</sup> and the other recommended no acute anticoagulation.<sup>251</sup> Specifically, the American College of Chest Physicians recommended initial anticoagulation except in the presence of significant hemorrhage, in which case monitoring for propagation was suggested, with initiation of anticoagulation if propagation should occur. Anticoagulation was recommended for a minimum of 6 weeks and no longer than 3 months. It was suggested that a venous imaging study be performed at 6 weeks, and if full recanalization is seen, anticoagulation can be discontinued. The AHA guidelines make no recommendations regarding initial anticoagulation. Anticoagulation is considered reasonable in neonates with thrombus propagation or thrombophilia (which cannot always be diagnosed during acute illness). The reluctance to treat neonatal CVT with anticoagulation was based on several concerns. First, there was an absence of safety data for neonates, and second, there was concern regarding increased susceptibility of the neonatal brain to hemorrhage. Before the current outcome literature, another reason not to treat neonates was the erroneous perception that neonates have a good outcome from CVT and treatment is therefore unnecessary. As noted in previous sections, these assumptions have been refuted in part by studies published in the past few years. However, in the absence of clinical trial evidence, practice variability is understandable.<sup>251</sup>

#### Recommendations

1. Supportive measures for children with CVT should include appropriate hydration, control of epileptic

seizures, and treatment of elevated intracranial pressure (Class I; Level of Evidence C).

2. Given the potential for visual loss owing to severe or long-standing increased intracranial pressure in children with CVT, periodic assessments of the visual fields and visual acuity should be performed, and appropriate measures to control elevated intracranial pressure and its complications should be instituted (Class I; Level of Evidence C).
3. In all pediatric patients, if initial anticoagulation treatment is withheld, repeat neuroimaging including venous imaging in the first week after diagnosis is recommended to monitor for propagation of the initial thrombus or new infarcts or hemorrhage (Class I; Level of Evidence C).
4. In children with acute CVT diagnosed beyond the first 28 days of life, it is reasonable to treat with full-dose LMWH even in the presence of intracranial hemorrhage (Class IIa; Level of Evidence C).
5. In children with acute CVT diagnosed beyond the first 28 days of life, it is reasonable to continue LMWH or oral vitamin K antagonists for 3 to 6 months (Class IIa; Level of Evidence C).
6. In all pediatric patients with acute CVT, if initial anticoagulation is started, it is reasonable to perform a head CT or MRI scan in the initial week after treatment to monitor for additional hemorrhage (Class IIa; Level of Evidence C).
7. Children with CVT may benefit from thrombophilia testing to identify underlying coagulation defects, some of which could affect the risk of subsequent rethromboses and influence therapeutic decisions<sup>250–252</sup> (Class IIb; Level of Evidence B).
8. Children with CVT may benefit from investigation for underlying infections with blood cultures and sinus radiographs<sup>92,237,267</sup> (Class IIb; Level of Evidence B).
9. In neonates with acute CVT, treatment with LMWH or UFH may be considered<sup>72,179,201,236,263</sup> (Class IIb; Level of Evidence B).
10. Given the frequency of epileptic seizures in children with an acute CVT, continuous electroencephalography monitoring may be considered for individuals who are unconscious or mechanically ventilated (Class IIb; Level of Evidence C).
11. In neonates with acute CVT, continuation of LMWH for 6 weeks to 3 months may be considered (Class IIb; Level of Evidence C).
12. The usefulness and safety of endovascular intervention are uncertain in pediatric patients, and its use may only be considered in carefully selected patients with progressive neurological deterioration despite intensive and therapeutic levels of anticoagulant treatment (Class IIb; Level of Evidence C).

#### Clinical Outcomes: Prognosis

There are several studies and reviews on the outcome and prognosis of CVT.<sup>181,256,257</sup> The majority of such studies are retrospective (totally or in part).<sup>14,63,66,90,136,175,179,190,194,233,270–274</sup> Of the few prospective studies, some did not analyze prognostic factors<sup>178,193,261</sup> or performed only a bivariate analysis of such predictors<sup>275,276</sup> or analyzed specific subgroups of patients.<sup>42,84,89,192</sup> There are only 5 cohort studies<sup>5,55,93,167,203</sup>

**Table 6. Variables Associated With Poor Prognosis in Cohort Studies**

Demographic	Clinical	Neuroimaging	Risk Factors
Age >37 y <sup>10</sup>	Coma <sup>10,117,277</sup>	Intracerebral hemorrhage <sup>10,277</sup>	Cancer <sup>10,177</sup>
Male sex <sup>10</sup>	Neurological deficit and severity (NIHSS) <sup>177,179</sup>	Involvement of the straight sinus <sup>277</sup>	CNS infection <sup>10</sup>
	Encephalopathy <sup>117</sup>	Thrombosis of the deep venous system <sup>10</sup>	Underlying coagulopathy hereditary thrombophilia <sup>66</sup>
	Decreased level of consciousness <sup>10</sup>		
	Hemiparesis <sup>10</sup>	Venous infarction <sup>66,179</sup>	
	Seizures <sup>10,179</sup>		

NIHSS indicates National Institutes of Health Stroke Scale; CNS, central nervous system.

that analyzed prognostic factors for the short-term<sup>5</sup> and the long-term outcome of CVT patients (Table 6).<sup>6,10,117,177,277</sup>

### Neurological Worsening After Diagnosis

Neurological worsening may occur in 23% of patients, even several days after diagnosis. Neurological worsening can feature depressed consciousness, mental status disturbance, new seizure, worsening of or a new focal deficit, increase in headache intensity, or visual loss. Approximately one third of patients with neurological deterioration will have new parenchymal lesions when neuroimaging is repeated. Patients with depressed consciousness on admission are more likely to deteriorate.<sup>1,278</sup>

### Early Death

Approximately 3% to 15% of patients die in the acute phase of the disorder.<sup>28</sup> Most early deaths are a consequence of CVT. In the ISCVT,<sup>10</sup> 21 (3.4%) of 624 patients died within 30 days from symptom onset; however, in a recent retrospective/prospective multicenter study<sup>16</sup> from the United States, higher mortality (13%) was reported. Case series from developing countries also have higher figures for early deaths, with 6% reported in a large Pakistan-Middle East registry<sup>63</sup> and 15% in a single-center case series from Iran.<sup>261</sup>

In the largest study, the ISCVT, risk factors for 30-day mortality were depressed consciousness, altered mental status, and thrombosis of the deep venous system, right hemisphere hemorrhage, and posterior fossa lesions. The main cause of acute death with CVT is transtentorial herniation secondary to a large hemorrhagic lesion,<sup>5</sup> followed by herniation due to multiple lesions or to diffuse brain edema. Status epilepticus, medical complications, and PE are among other causes of early death.<sup>136,279</sup>

### Late Deaths

Deaths after the acute phase are predominantly related to the underlying conditions, in particular malignancies.<sup>10,14</sup>

### Long-Term Outcome

In the ISCVT study,<sup>55</sup> complete recovery at last follow-up (median 16 months) was observed in 79% of the patients; however, there was an 8.3% overall death rate and a 5.1% dependency rate (mRS score  $\geq 3$ ) at the end of follow-up (12.6% if we consider patients who survived with an mRS score  $\geq 2$ ). In a systematic review that included both retrospective and prospective studies, overall mortality was 9.4%, and the proportion of dependency (mRS score  $\geq 3$  or Glasgow Outcome Scale score  $\geq 3$ ) was 9.7%.<sup>28</sup> Two retrospec-

tive/prospective studies were reported after this review. In the Pakistan-Middle East registry,<sup>63</sup> the dependency rate (mRS score  $\geq 3$ ) was higher (11%), whereas in the US multicenter registry,<sup>16</sup> 28% of patients were dependent at 12 months. Of note, some studies include patients transferred to tertiary care centers, whose strokes are usually more severe, with the potential for a referral bias. Among the 7 cohort studies (including the prospective part of retrospective/prospective studies in which information can be analyzed separately), the overall death and dependency rate was 15% (95% CI 13% to 18%).<sup>10</sup>

### Neuropsychological and Neuropsychiatric Sequelae

There is little information on the long-term neuropsychological and neuropsychiatric outcome in CVT survivors.<sup>260,272</sup> Despite the apparent general good recovery in most patients with CVT, approximately one half of survivors feel depressed or anxious, and minor cognitive or language deficits may preclude them from resuming their previous jobs.<sup>260,272</sup>

Abulia, executive deficits, and amnesia may result from thrombosis of the deep venous system, with bilateral panthalamic infarcts. Memory deficits, behavioral problems, or executive deficits may persist.<sup>263,280</sup>

Aphasia, in general of the fluent type, results from left lateral sinus thrombosis with temporal infarct or hemorrhage. Recovery is usually favorable, but minor troubles in spontaneous speech and naming might persist.

### Risk Factors for Long-Term Poor Outcomes

Risk factors for poor long-term prognosis in the ISCVT cohort were central nervous system infection, any malignancy, thrombosis of the deep venous system, intracranial hemorrhage on admission CT/MRI, Glasgow Coma Scale score  $< 9$ , mental status disturbance, age  $> 37$  years, and male sex.<sup>55</sup> Brain herniation leading to early death was more frequent in young patients, whereas late deaths due to malignancies and less favorable functional outcome were more frequent in elderly patients.<sup>6,10,89</sup> Table 6 summarizes demographic, imaging, and clinical variables associated with poor prognosis.<sup>281,282</sup> A Glasgow Coma Scale score of 14 to 15 on admission, a complete or partial intracranial hypertension syndrome (including isolated headache) as the only manifestation of CVT, and absence of aphasia were variables associated with a favorable outcome.<sup>117,177</sup>

### Risk Score Models

Despite the overall favorable outcome,  $\approx 15\%$  of CVT patients die or become dependent after CVT.<sup>10,283</sup> Risk stratification scores might improve the ability to inform CVT

patients of their individual prognosis and to select those who might benefit most from intensive monitoring and invasive treatments. One study created and validated a risk score model to predict a poor outcome. The risk score model range from 0 (lowest risk) to 9 (highest risk), and a cutoff of  $\geq 3$  points indicated a higher risk of death or dependency at 6 months. Two points were assigned for the presence of malignancy, coma, or thrombosis of the deep venous system and 1 point for male sex, presence of decreased level of consciousness, or ICH. The predictive ability (c-statistics) in the derivation cohort was 85.4%, 84.4%, and 90.1% in the validation samples. Sensitivity and specificity in the combined samples were 96.1% and 13.6%, respectively.

Another study<sup>284</sup> incorporated age  $>37$  years and central nervous system infection into this model and assigned a weighted index to each variable. The study validated the score in 90 CVT patients and obtained an area under the receiver operator characteristic curve of 0.81 to predict mortality. With a cutoff score of  $\geq 14$ , sensitivity was 88% and specificity was 70%. The predictive value for good outcome, defined as an mRS score  $<2$ , was 95%, and for bad outcome, it was 39%.

### Recanalization

In a systematic review of 5 small studies,<sup>28</sup> recanalization rates of CVT at 3 months and 1 year of follow-up were 84% and 85%, respectively. The highest rates of recanalization are observed in deep cerebral veins and cavernous sinus thrombosis and the lowest rates in lateral sinus thrombosis.<sup>193</sup> In adults, recanalization of the occluded sinus is not related to outcome after CVT.<sup>41,194</sup>

### Summary/Future Considerations

This statement provides an extensive and critical review of the literature related to the diagnosis and management of CVT and its most common complications.

A dural sinus or cerebral venous thrombosis (CVT) accounts for 0.5% to 1% of all strokes, mostly affecting young individuals and women of childbearing age.<sup>1,4,6</sup> Patients with CVT commonly present with headache, although some develop a focal neurological deficit, decreased level of consciousness, seizures, or intracranial hypertension without focal neurological signs.<sup>1,4,6</sup> Uncommonly, an insidious onset may create a diagnostic challenge. A prothrombotic factor or a direct cause is identified in approximately two thirds of patients with sinus thrombosis. The diagnosis is usually made by venographic studies with CT (CTV) or MRI (MRV) to demonstrate obstruction of the venous sinuses or cerebral veins by thrombus.<sup>70,96</sup> Management of CVT includes treatment of the underlying condition; symptomatic treatment; the prevention or treatment of complications of increased intracranial pressure, ICH, or venous infarction; and typically, anticoagulation therapy (see algorithm in Figure 4).

Diagnostic and therapeutic techniques in stroke are in continuous evolution. Important advances have been made in the understanding of the pathophysiology of cerebral sinus thrombosis. Yet promising techniques (endovascular procedures, hemicraniectomy for the management of refractory intracranial hypertension in the context of mass effect or ICH, etc) need to be evaluated rigorously before they are widely adopted.

Despite substantial progress in the study of CVT in recent years, much of the literature remains descriptive. The CVT writing group made an effort to highlight areas that require further study (eg, larger randomized clinical trials to determine the benefit of therapeutic interventions) and provided suggestions that reflect the current standard practice. A randomized clinical trial aimed at comparing the benefit of anticoagulation therapy versus endovascular thrombolysis (TO-ACT Trial; Thrombolysis Or Anticoagulation for Cerebral Venous Thrombosis) is under way. The results of TO-ACT may contribute to improving the acute management of patients with CVT.

Management dilemmas in CVT can be complex. Healthcare providers managing these patients may require assistance from appropriate subspecialists given that there is no strong literature evidence to guide some of these challenging clinical decisions. The present statement is unlikely to end the debate about the management of CVT. Rather, the content of the present statement should be seen as a compilation of the best available evidence at the present time. Through a process of innovative research and systematic evaluation, diagnosis, management, and therapeutic alternatives will continue to evolve and consequently lead to better outcomes for patients with CVT.

## Appendix

### Search Strategy

To address the diagnosis and management of CVT, we systematically searched in PubMed on the following terms: “cerebral vein thrombosis” OR “cerebral venous thrombosis” OR “sinus thrombosis.” Then, we refined our search by combining these with “epidemiology,” “management,” “diagnosis,” “imaging,” “MRI,” “randomized trial,” “prognosis,” and “outcome.” These terms were searched with regard to adults, pregnant women, children, and neonates. Our last search was undertaken on July 7, 2010. No language restriction was placed on the searches. Because the intention was to guide readers on the management of CVT based on a comprehensive review of the literature, including sometimes specific and/or uncommon clinical situations, no formal restrictions or further quality assessment was undertaken.

For the treatment section, we reviewed systematic reviews and guideline statements of the Cochrane Collaboration,<sup>161</sup> the AHA/American Stroke Association,<sup>285</sup> the American College of Chest Physicians,<sup>162,163</sup> and the European Federation of Neurological Sciences,<sup>164</sup> in addition to literature reviews and treatment guidelines. For specific therapeutic alternatives, we combined (“cerebral vein thrombosis” OR “cerebral venous thrombosis” OR “sinus thrombosis”) with “hemicraniectomy,” “thrombolysis,” or “endovascular.” Secondary sources of data included reference lists of articles reviewed and cohort studies that related treatment to outcomes.

Authors assigned to each section were responsible for checking for additional references for their specific topic. For the section on “CVT in the Pediatric Population,” we also reviewed the guideline statements of the AHA<sup>267</sup> and the “American College of Chest Physicians Evidence-Based Clinical Practice Guidelines (8th Edition)” on anti-thrombotic therapy in neonates and children.<sup>269</sup> For the section on “CVT During Pregnancy,” we also reviewed the guideline statements from the American College of Chest Physicians.<sup>241a</sup>

## Disclosures

## Writing Group Disclosures

Writing Group Member	Employment	Research Grant	Other Research Support	Speakers' Bureau/Honoraria	Expert Witness	Ownership Interest	Consultant/Advisory Board	Other
Gustavo Saposnik	University of Toronto	None	None	None	None	None	None	None
Fernando Barinagarrementeria	Universidad del Valle de Mexico	None	None	None	None	None	None	None
Robert D. Brown, Jr	Mayo Clinic	None	None	None	None	None	None	None
Cheryl D. Bushnell	Wake Forest University	AHA/Bugher Foundation†; NIH‡	Bristol-Myers Squibb/Sanofi*	None	None	None	Boehringer Ingelheim*	None
Brett Cucchiara	University of Pennsylvania	None	None	None	None	None	None	None
Mary Cushman	University of Vermont	NIH‡	None	None	None	None	None	None
Gabrielle deVeber	Hospital for Sick Children, Toronto	None	None	None	<\$10 000 CSVT legal case*	None	None	None
Jose M. Ferro	University of Lisbon, Portugal	None	None	None	None	None	Servier*; Tecnifar*	None
Fong Y. Tsai	University of California at Irvine	None	None	None	None	None	None	None

This table represents the relationships of writing group members that may be perceived as actual or reasonably perceived conflicts of interest as reported on the Disclosure Questionnaire, which all members of the writing group are required to complete and submit. A relationship is considered to be "Significant" if (a) the person receives \$10 000 or more during any 12-month period, or 5% or more of the person's gross income; or (b) the person owns 5% or more of the voting stock or share of the entity, or owns \$10 000 or more of the fair market value of the entity. A relationship is considered to be "Modest" if it is less than "Significant" under the preceding definition.

\*Modest.

†Significant.

## Reviewer Disclosures

Reviewer	Employment	Research Grant	Other Research Support	Speakers' Bureau/Honoraria	Expert Witness	Ownership Interest	Consultant/Advisory Board	Other
Kenneth A. Bauer	Beth Israel Deaconess Medical Center	None	None	None	None	None	None	None
Guilherme Dabus	Baptist Cardiac and Vascular Institute	None	None	None	None	None	None	None
Adnan I. Qureshi	University of Minnesota	Protein Design Labs*	None	None	None	None	None	None
Brian Silver	Henry Ford Medical Center	None	None	None	None	None	None	None
Greg Zipfel	Washington University	None	None	None	None	None	None	None

This table represents the relationships of reviewers that may be perceived as actual or reasonably perceived conflicts of interest as reported on the Disclosure Questionnaire, which all reviewers are required to complete and submit. A relationship is considered to be "Significant" if (a) the person receives \$10 000 or more during any 12-month period, or 5% or more of the person's gross income; or (b) the person owns 5% or more of the voting stock or share of the entity, or owns \$10 000 or more of the fair market value of the entity. A relationship is considered to be "Modest" if it is less than "Significant" under the preceding definition.

\*Modest.

## References

- Bousser MG, Ferro JM. Cerebral venous thrombosis: an update. *Lancet Neurol*. 2007;6:162–170.
- Stam J. Thrombosis of the cerebral veins and sinuses. *N Engl J Med*. 2005;352:1791–1798.
- Stam J. Cerebral venous and sinus thrombosis: incidence and causes. *Adv Neurol*. 2003;92:225–232.
- Ferro JM. Causes, predictors of death, and antithrombotic treatment in cerebral venous thrombosis. *Clin Adv Hematol Oncol*. 2006;4:732–733.
- Gibbons RJ, Smith S, Antman E. American College of Cardiology/American Heart Association clinical practice guidelines: part I: where do they come from? *Circulation*. 2003;107:2979–2986.
- Canhão P, Ferro JM, Lindgren AG, Bousser MG, Stam J, Barinagarrementeria F; ISCVT Investigators. Causes and predictors of death in cerebral venous thrombosis. *Stroke*. 2005;36:1720–1725.
- Towbin A. The syndrome of latent cerebral venous thrombosis: its frequency and relation to age and congestive heart failure. *Stroke*. 1973;4:419–430.
- Cantu C, Arauz A, Ruiz-Sandoval JL, Barinagarrementeria F, Villarreal J, Rangel R, Murillo-Bonilla L. Clinical outcome and stroke types in Hispanic mestizos. Presented at: Joint World Congress of Stroke; October 26–29, 2006; Cape Town, South Africa.
- Janghorbani M, Zare M, Saadatnia M, Mousavi SA, Mojarrad M, Asgari E. Cerebral vein and dural sinus thrombosis in adults in Isfahan, Iran: frequency and seasonal variation. *Acta Neurol Scand*. 2008;117:117–121.
- Ferro JM, Canhão P, Stam J, Bousser MG, Barinagarrementeria F; ISCVT Investigators. Prognosis of cerebral vein and dural sinus thrombosis: results of the International Study on Cerebral Vein and Dural Sinus Thrombosis (ISCVT). *Stroke*. 2004;35:664–670.
- de Freitas GR, Bogousslavsky J. Risk factors of cerebral vein and sinus thrombosis. *Front Neurol Neurosci*. 2008;23:23–54.
- Bombeli T, Basic A, Fehr J. Prevalence of hereditary thrombophilia in patients with thrombosis in different venous systems. *Am J Hematol*. 2002;70:126–132.
- Martinelli I, Battaglioli T, Pedotti P, Cattaneo M, Mannucci PM. Hyperhomocysteinemia in cerebral vein thrombosis. *Blood*. 2003;102:1363–1366.
- Wasay M, Bakshi R, Bobustuc G, Kojan S, Sheikh Z, Dai A, Cheema Z. Cerebral venous thrombosis: analysis of a multicenter cohort from the United States. *J Stroke Cerebrovasc Dis*. 2008;17:49–54.
- Christopher R, Nagaraja D, Dixit NS, Narayanan CP. Anticardiolipin antibodies: a study in cerebral venous thrombosis. *Acta Neurol Scand*. 1999;99:121–124.
- Boncoraglio G, Carriero MR, Chiapparini L, Ciceri E, Ciusani E, Erbetta A, Parati EA. Hyperhomocysteinemia and other thrombophilic risk factors in 26 patients with cerebral venous thrombosis. *Eur J Neurol*. 2004;11:405–409.
- Ventura P, Cobelli M, Marietta M, Panini R, Rosa MC, Salvioli G. Hyperhomocysteinemia and other newly recognized inherited coagulation disorders (factor V Leiden and prothrombin gene mutation) in patients with idiopathic cerebral vein thrombosis. *Cerebrovasc Dis*. 2004;17:153–159.
- Gadelha T, André C, Jucá AA, Nucci M. Prothrombin 20210A and oral contraceptive use as risk factors for cerebral venous thrombosis. *Cerebrovasc Dis*. 2005;19:49–52.
- Dahlbäck B, Carlsson M, Svensson PJ. Familial thrombophilia due to a previously unrecognized mechanism characterized by poor anticoagulant response to activated protein C: prediction of a cofactor to activated protein C. *Proc Natl Acad Sci U S A*. 1993;90:1004–1008.
- Bertina RM, Koeleman BP, Koster T, Rosendaal FR, Dirven RJ, de Ronde H, van der Velden PA, Reitsma PH. Mutation in blood coagulation factor V associated with resistance to activated protein C. *Nature*. 1994;369:64–67.
- Poort SR, Rosendaal FR, Reitsma PH, Bertina RM. A common genetic variation in the 3'-untranslated region of the prothrombin gene is associated with elevated plasma prothrombin levels and an increase in venous thrombosis. *Blood*. 1996;88:3698–3703.
- Weih M, Vetter B, Ziemer S, Mehraein S, Valdeza JM, Koscielny J, Kulozik AE, Einhäupl KM. Increased rate of factor V Leiden mutation in patients with cerebral venous thrombosis. *J Neurol*. 1998;245:149–152.
- Rodrigues CA, Rocha LK, Morelli VM, Franco RF, Lourenço DM. Prothrombin G20210A mutation, and not factor V Leiden mutation, is a risk factor for cerebral venous thrombosis in Brazilian patients. *J Thromb Haemost*. 2004;2:1211–1212.
- Meng Q, Pu C. Cerebral venous thrombosis and factor V Leiden mutation [in Chinese]. *Zhonghua Yi Xue Za Zhi*. 2002;82:47–49.
- Voetsch B, Damasceno BP, Camargo EC, Massaro A, Bacheschi LA, Scaff M, Annichino-Bizzacchi JM, Arruda VR. Inherited thrombophilia as a risk factor for the development of ischemic stroke in young adults. *Thromb Haemost*. 2000;83:229–233.
- Zuber M, Toulon P, Marnet L, Mas JL. Factor V Leiden mutation in cerebral venous thrombosis. *Stroke*. 1996;27:1721–1723.
- Martinelli I, Landi G, Merati G, Cella R, Tosetto A, Mannucci PM. Factor V gene mutation is a risk factor for cerebral venous thrombosis. *Thromb Haemost*. 1996;75:393–394.
- Dentali F, Crowther M, Ageno V. Thrombophilic abnormalities, oral contraceptives, and risk of cerebral vein thrombosis: a meta-analysis. *Blood*. 2006;107:2766–2773.
- Cantu C, Alonso E, Jara A, Martínez L, Ríos C, Fernández M, García I, Barinagarrementeria F. Hyperhomocysteinemia, low folate and vitamin B12 concentrations, and methylene tetrahydrofolate reductase mutation in cerebral venous thrombosis. *Stroke*. 2004;35:1790–1794.
- Nagaraja D, Noone ML, Bharatkumar VP, Christopher R. Homocysteine, folate and vitamin B(12) in puerperal cerebral venous thrombosis. *J Neurol Sci*. 2008;272:43–47.
- James AH, Bushnell CD, Jamison MG, Myers ER. Incidence and risk factors for stroke in pregnancy and the puerperium. *Obstet Gynecol*. 2005;106:509–516.
- Cantú C, Barinagarrementeria F. Cerebral venous thrombosis associated with pregnancy and puerperium: review of 67 cases. *Stroke*. 1993;24:1880–1884.
- Jaigobin C, Silver FL. Stroke and pregnancy. *Stroke*. 2000;31:2948–2951.
- Davie CA, O'Brien P. Stroke and pregnancy. *J Neurol Neurosurg Psychiatry*. 2008;79:240–245.
- Lanska DJ, Kryscio RJ. Risk factors for peripartum and postpartum stroke and intracranial venous thrombosis. *Stroke*. 2000;31:1274–1282.
- Martinelli I, Sacchi E, Landi G, Taioli E, Duca F, Mannucci PM. High risk of cerebral-vein thrombosis in carriers of a prothrombin-gene mutation and in users of oral contraceptives. *N Engl J Med*. 1998;338:1793–1797.
- de Bruijn SF, Stam J, Koopman MM, Vandembroucke JP; the Cerebral Venous Sinus Thrombosis Study Group. Case-control study of risk of cerebral sinus thrombosis in oral contraceptive users and in [correction of who are] carriers of hereditary prothrombotic conditions. *BMJ*. 1998;316:589–592.
- Reuner KH, Ruf A, Grau A, Rickmann H, Stolz E, Jüttler E, Druschky KF, Patscheke H. Prothrombin gene G20210→A transition is a risk factor for cerebral venous thrombosis. *Stroke*. 1998;29:1765–1769.
- Kim AW, Trobe JD. Syndrome simulating pseudotumor cerebri caused by partial transverse venous sinus obstruction in metastatic prostate cancer. *Am J Ophthalmol*. 2000;129:254–256.
- Meininger V, James JM, Rio B, Zittoun R. Dural venous sinus occlusions in hemopathies [in French]. *Rev Neurol (Paris)*. 1985;141:228–233.
- Raizer JJ, DeAngelis LM. Cerebral sinus thrombosis diagnosed by MRI and MR venography in cancer patients. *Neurology*. 2000;54:1222–1226.
- Damak M, Crassard I, Wolff V, Bousser MG. Isolated lateral sinus thrombosis: a series of 62 patients. *Stroke*. 2009;40:476–481.
- Wasay M, Dai AI, Ansari M, Shaikh Z, Roach ES. Cerebral venous sinus thrombosis in children: a multicenter cohort from the United States. *J Child Neurol*. 2008;23:26–31.
- Manolidis S, Kutz JW Jr. Diagnosis and management of lateral sinus thrombosis. *Otol Neurotol*. 2005;26:1045–1051.
- Kueper M, Goericke SL, Kastrup O. Cerebral venous thrombosis after epidural blood patch: coincidence or causal relation? A case report and review of the literature. *Cephalalgia*. 2008;28:769–773.
- Lan MY, Chang YY, Liu JS. Delayed cerebral venous thrombosis in a patient with spontaneous intracranial hypotension. *Cephalalgia*. 2007;27:1176–1178.
- Wilder-Smith E, Kothbauer-Margreiter I, Lämmle B, Sturzenegger M, Ozdoba C, Hauser SP. Dural puncture and activated protein C resistance: risk factors for cerebral venous sinus thrombosis. *J Neurol Neurosurg Psychiatry*. 1997;63:351–356.
- Misra UK, Kalita J, Bansal V, Nair PP. Paroxysmal nocturnal haemoglobinuria presenting as cerebral venous sinus thrombosis. *Transfus Med*. 2008;18:308–311.

49. Ogata T, Kamouchi M, Kitazono T, Kuroda J, Ooboshi H, Shono T, Morioka T, Ibayashi S, Sasaki T, Iida M. Cerebral venous thrombosis associated with iron deficiency anemia. *J Stroke Cerebrovasc Dis*. 2008;17:426–428.
50. Alper G, Berrak SG, Ekinci G, Canpolat C, Erzen C. Sagittal sinus thrombosis associated with thrombocytopenia: a report of two patients. *Pediatr Neurol*. 1999;21:573–575.
51. Zaragoza-Casares P, Gómez-Fernández T, Zato-Gómez de Líaño MA, Zaragoza-García P. Superior sagittal sinus thrombosis and bilateral sixth-nerve palsy in a child with nephrotic syndrome. *Pediatr Nephrol*. 2007;22:753–755.
52. Appenzeller S, Faria A, Marini R, Costallat LT, Cendes F. Focal transient lesions of the corpus callosum in systemic lupus erythematosus. *Clin Rheumatol*. 2006;25:568–571.
53. Borhani-Haghighi A, Samangoie S, Ashjazadeh N, Nikseresht A, Shariat A, Yousefipour G, Safari A. Neurological manifestations of Behçet's disease. *Saudi Med J*. 2006;27:1542–1546.
54. Grimes DA, Schulz KF. Bias and causal associations in observational research. *Lancet*. 2002;359:248–252.
55. Varga EA, Moll S. Cardiology patient pages: prothrombin 20210 mutation (factor II mutation). *Circulation*. 2004;110:e15–e18.
56. Tosetto A, Missiaglia E, Frezzato M, Rodeghiero F. The VITA project: prothrombin G20210A mutation and venous thromboembolism in the general population. *Thromb Haemost*. 1999;82:1395–1398.
57. Pabinger I, Grafenhofer H, Kyrle PA, Quehenberger P, Mannhalter C, Lechner K, Kaider A. Temporary increase in the risk for recurrence during pregnancy in women with a history of venous thromboembolism. *Blood*. 2002;100:1060–1062.
58. Ruíz-Sandoval JL, Cantú C, Barinagarrementeria F. Intracerebral hemorrhage in young people: analysis of risk factors, location, causes, and prognosis. *Stroke*. 1999;30:537–541.
59. Gillum LA, Mamidipudi SK, Johnston SC. Ischemic stroke risk with oral contraceptives: a meta-analysis. *JAMA*. 2000;284:72–78.
60. Rogers LR. Cerebrovascular complications in patients with cancer. *Semin Neurol*. 2004;24:453–460.
61. Gosk-Bierska I, Wysokinski W, Brown RD Jr, Karnicki K, Grill D, Wiste H, Wysokinska E, McBane RD 2nd. Cerebral venous sinus thrombosis: incidence of venous thrombosis recurrence and survival. *Neurology*. 2006;67:814–819.
62. De Cruz P, Lust M, Trost N, Wall A, Gerraty R, Connell WR. Cerebral venous thrombosis associated with ulcerative colitis. *Intern Med J*. 2008;38:865–867.
63. Khealani BA, Wasay M, Saadah M, Sultana E, Mustafa S, Khan FS, Kamal AK. Cerebral venous thrombosis: a descriptive multicenter study of patients in Pakistan and Middle East. *Stroke*. 2008;39:2707–2711.
64. Cumurciuc R, Crassard I, Sarov M, Valade D, Bousser MG. Headache as the only neurological sign of cerebral venous thrombosis: a series of 17 cases. *J Neurol Neurosurg Psychiatry*. 2005;76:1084–1087.
65. Crassard I, Bousser MG. Headache in patients with cerebral venous thrombosis [in French]. *Rev Neurol (Paris)*. 2005;161:706–708.
66. Appenzeller S, Zeller CB, Annichino-Bizzachi JM, Costallat LT, Deus-Silva L, Voetsch B, Faria AV, Zanardi VA, Damasceno BP, Cendes F. Cerebral venous thrombosis: influence of risk factors and imaging findings on prognosis. *Clin Neurol Neurosurg*. 2005;107:371–378.
67. Biousse V, Ameri A, Bousser MG. Isolated intracranial hypertension as the only sign of cerebral venous thrombosis. *Neurology*. 1999;53:1537–1542.
68. Patronas NJ, Duda EE, Mirfakhraee M, Wollmann RL. Superior sagittal sinus thrombosis diagnosed by computed tomography. *Surg Neurol*. 1981;15:11–14.
69. Teichgraber JF, Per-Lee JH, Turner JS Jr. Lateral sinus thrombosis: a modern perspective. *Laryngoscope*. 1982;92(pt 1):744–751.
70. Leach JL, Fortuna RB, Jones BV, Gaskill-Shibley MF. Imaging of cerebral venous thrombosis: current techniques, spectrum of findings, and diagnostic pitfalls. *Radiographics*. 2006;26(suppl 1):S19–S41.
71. Sagduyu A, Sirin H, Mulayim S, Bademkiran F, Yuntun N, Kitis O, Calli C, Dalbasti T, Kumral E. Cerebral cortical and deep venous thrombosis without sinus thrombosis: clinical MRI correlates. *Acta Neurol Scand*. 2006;114:254–260.
72. van den Bergh WM, van der Schaaf I, van Gijn J. The spectrum of presentations of venous infarction caused by deep cerebral vein thrombosis. *Neurology*. 2005;65:192–196.
73. Crombé D, Haven F, Gille M. Isolated deep cerebral venous thrombosis diagnosed on CT and MR imaging: a case study and literature review. *JBR-BTR*. 2003;86:257–261.
74. Tsai FY, Kostanian V, Rivera M, Lee KW, Chen CC, Nguyen TH. Cerebral venous congestion as indication for thrombolytic treatment. *Cardiovasc Intervent Radiol*. 2007;30:675–687.
75. Yamini B, Loch Macdonald R, Rosenblum J. Treatment of deep cerebral venous thrombosis by local infusion of tissue plasminogen activator. *Surg Neurol*. 2001;55:340–346.
76. Jones BV. Case 62: lobar hemorrhage from thrombosis of the vein of Labbé. *Radiology*. 2003;228:693–696.
77. Cucchiara B, Messe S, Taylor R, Clarke J, Pollak E. Utility of D-dimer in the diagnosis of cerebral venous sinus thrombosis. *J Thromb Haemost*. 2005;3:387–389.
78. Lalive PH, de Moerloose P, Lovblad K, Sarasin FP, Mermillod B, Sztajzel R. Is measurement of D-dimer useful in the diagnosis of cerebral venous thrombosis? *Neurology*. 2003;61:1057–1060.
79. Tardy B, Tardy-Poncet B, Viallon A, Piot M, Garnier P, Mohamedi R, Guyomarc'h S, Venet C. D-dimer levels in patients with suspected acute cerebral venous thrombosis. *Am J Med*. 2002;113:238–241.
80. Wildberger JE, Mull M, Kilbinger M, Schon S, Vorwerk D. Cerebral sinus thrombosis: rapid test diagnosis by demonstration of increased plasma D-dimer levels (SimpliRED) [in German]. *Rofo*. 1997;167:527–529.
81. Talbot K, Wright M, Keeling D. Normal d-dimer levels do not exclude the diagnosis of cerebral venous sinus thrombosis. *J Neurol*. 2002;249:1603–1604.
82. Kosinski CM, Mull M, Schwarz M, Koch B, Biniak R, Schäfer J, Milkereit E, Willmes K, Schiefer J. Do normal D-dimer levels reliably exclude cerebral sinus thrombosis? *Stroke*. 2004;35:2820–2825.
83. Crassard I, Soria C, Tzourio C, Woimant F, Drouet L, Ducros A, Bousser MG. A negative D-dimer assay does not rule out cerebral venous thrombosis: a series of seventy-three patients. *Stroke*. 2005;36:1716–1719.
84. Giroi M, Ferro JM, Canhão P, Stam J, Bousser MG, Barinagarrementeria F, Leys D; ISCVT Investigators. Predictors of outcome in patients with cerebral venous thrombosis and intracerebral hemorrhage. *Stroke*. 2007;38:337–342.
85. Lin A, Foroosan R, Danesh-Meyer HV, De Salvo G, Savino PJ, Sergott RC. Occurrence of cerebral venous sinus thrombosis in patients with presumed idiopathic intracranial hypertension. *Ophthalmology*. 2006;113:2281–2284.
86. Nagi S, Kaddour C, Soukri I, Ben Ghorbal I, Sebai R, Belghith L, Skandrani L, Touibi S. Deep cerebral venous system thrombosis: report of two cases [in French]. *J Radiol*. 2006;87:1084–1088.
87. Nakazato Y, Sonoda K, Senda M, Tamura N, Araki N, Tanahashi N, Shimazu K. Case of straight sinus venous thrombosis presenting as depression and disorientation due to bilateral thalamic lesions [in Japanese]. *Rinsho Shinkeigaku*. 2006;46:652–654.
88. Kothare SV, Ebb DH, Rosenberger PB, Buonanno F, Schaefer PW, Krishnamoorthy KS. Acute confusion and mutism as a presentation of thalamic strokes secondary to deep cerebral venous thrombosis. *J Child Neurol*. 1998;13:300–303.
89. Ferro JM, Canhão P, Bousser MG, Stam J, Barinagarrementeria F; ISCVT Investigators. Cerebral vein and dural sinus thrombosis in elderly patients. *Stroke*. 2005;36:1927–1932.
90. Terazzi E, Mittino D, Rudá R, Cerrato P, Monaco F, Sciolla R, Grasso E, Leone MA; Cerebral Venous Thrombosis Group. Cerebral venous thrombosis: a retrospective multicentre study of 48 patients. *Neurol Sci*. 2005;25:311–315.
91. Tsai FY, Nguyen B, Lin WC, Hsueh CJ, Yen A, Meng K, Kostanian V. Endovascular procedures for cerebrovenous disorders. *Acta Neurochir Suppl*. 2008;101:83–86.
92. Justich E, Lammer J, Fritsch G, Beitzke A, Walter GF. CT diagnosis of thrombosis of dural sinuses in childhood. *Eur J Radiol*. 1984;4:294–295.
93. Ford K, Sarwar M. Computed tomography of dural sinus thrombosis. *AJNR Am J Neuroradiol*. 1981;2:539–543.
94. Linn J, Ertl-Wagner B, Seelos KC, Strupp M, Reiser M, Brückmann H, Brüning R. Diagnostic value of multidetector-row CT angiography in the evaluation of thrombosis of the cerebral venous sinuses. *AJNR Am J Neuroradiol*. 2007;28:946–952.
95. Tsai FY, Wang AM, Matovich VB, Lavin M, Berberian B, Simonson TM, Yuh WT. MR staging of acute dural sinus thrombosis: correlation

- with venous pressure measurements and implications for treatment and prognosis. *AJNR Am J Neuroradiol.* 1995;16:1021–1029.
96. Lee SK, terBrugge KG. Cerebral venous thrombosis in adults: the role of imaging evaluation and management. *Neuroimaging Clin N Am.* 2003;13:139–152.
  97. Khandelwal N, Agarwal A, Kochhar R, Bapuraj JR, Singh P, Prabhakar S, Suri S. Comparison of CT venography with MR venography in cerebral sinovenous thrombosis. *AJR Am J Roentgenol.* 2006;187:1637–1643.
  98. Leys D, Cordonnier C. Cerebral venous thrombosis: update on clinical manifestations, diagnosis and management. *Ann Indian Acad Neurol.* 2008;11:S79–S87.
  99. Oppenheim C, Domigo V, Gauvrit JY, Lamy C, Mackowiak-Cordoliani MA, Pruvo JP, Méder JF. Subarachnoid hemorrhage as the initial presentation of dural sinus thrombosis. *AJNR Am J Neuroradiol.* 2005;26:614–617.
  100. Poon CS, Chang JK, Swarnkar A, Johnson MH, Wasenko J. Radiologic diagnosis of cerebral venous thrombosis: pictorial review. *AJR Am J Roentgenol.* 2007;189(suppl):S64–S75.
  101. Rodallec MH, Krainik A, Feydy A, Hélias A, Colombani JM, Jullès MC, Marteau V, Zins M. Cerebral venous thrombosis and multidetector CT angiography: tips and tricks. *Radiographics.* 2006;26(suppl 1):S5–S18.
  102. deVeber G, Andrew M, Adams C, Bjornson B, Booth F, Buckley DJ, Camfield CS, David M, Humphreys P, Langevin P, MacDonald EA, Gillett J, Meaney B, Shevell M, Sinclair DB, Yager J; Canadian Pediatric Ischemic Stroke Study Group. Cerebral sinovenous thrombosis in children. *N Engl J Med.* 2001;345:417–423.
  103. Majoie CB, van Straten M, Venema HW, den Heeten GJ. Multisection CT venography of the dural sinuses and cerebral veins by using matched mask bone elimination. *AJNR Am J Neuroradiol.* 2004;25:787–791.
  104. Manzione J, Newman GC, Shapiro A, Santo-Ocampo R. Diffusion- and perfusion-weighted MR imaging of dural sinus thrombosis. *AJNR Am J Neuroradiol.* 2000;21:68–73.
  105. Wasay M, Azeemuddin M. Neuroimaging of cerebral venous thrombosis. *J Neuroimaging.* 2005;15:118–128.
  106. Ozsvath RR, Casey SO, Lustrin ES, Alberico RA, Hassankhani A, Patel M. Cerebral venography: comparison of CT and MR projection venography. *AJR Am J Roentgenol.* 1997;169:1699–1707.
  107. Wetzel SG, Kirsch E, Stock KW, Kolbe M, Kaim A, Radue EW. Cerebral veins: comparative study of CT venography with intraarterial digital subtraction angiography. *AJNR Am J Neuroradiol.* 1999;20:249–255.
  108. Boukobza M, Crassard I, Bousser MG, Chabriat H. MR imaging features of isolated cortical vein thrombosis: diagnosis and follow-up. *AJNR Am J Neuroradiol.* 2009;30:344–348.
  109. Bousser MG. Cerebral venous thrombosis: diagnosis and management. *J Neurol.* 2000;247:252–258.
  110. Favrole P, Guichard JP, Crassard I, Bousser MG, Chabriat H. Diffusion-weighted imaging of intravascular clots in cerebral venous thrombosis. *Stroke.* 2004;35:99–103.
  111. Mullins ME, Grant PE, Wang B, Gonzalez RG, Schaefer PW. Parenchymal abnormalities associated with cerebral venous sinus thrombosis: assessment with diffusion-weighted MR imaging. *AJNR Am J Neuroradiol.* 2004;25:1666–1675.
  112. Nael K, Fenchel M, Salamon N, Duckwiler GR, Laub G, Finn JP, Villablanca JP. Three-dimensional cerebral contrast-enhanced magnetic resonance venography at 3.0 Tesla: initial results using highly accelerated parallel acquisition. *Invest Radiol.* 2006;41:763–768.
  113. Tomasian A, Salamon N, Krishnam MS, Finn JP, Villablanca JP. 3D high-spatial-resolution cerebral MR venography at 3T: a contrast-dose-reduction study. *AJNR Am J Neuroradiol.* 2009;30:349–355.
  114. Lettau M, Sartor K, Heiland S, Hähnel S. 3T high-spatial-resolution contrast-enhanced MR angiography of the intracranial venous system with parallel imaging. *AJNR Am J Neuroradiol.* 2009;30:185–187.
  115. Duncan IC, Fourie PA. Imaging of cerebral isolated cortical vein thrombosis. *AJR Am J Roentgenol.* 2005;184:1317–1319.
  116. Urban PP, Müller-Forell W. Clinical and neuroradiological spectrum of isolated cortical vein thrombosis. *J Neurol.* 2005;252:1476–1481.
  117. Ferro JM, Lopes MG, Rosas MJ, Ferro MA, Fontes J; Cerebral Venous Thrombosis Portuguese Collaborative Study Group. Long-term prognosis of cerebral vein and dural sinus thrombosis: results of the VENOPORT study. *Cerebrovasc Dis.* 2002;13:272–278.
  118. Hinman JM, Provenzale JM. Hypointense thrombus on T2-weighted MR imaging: a potential pitfall in the diagnosis of dural sinus thrombosis. *Eur J Radiol.* 2002;41:147–152.
  119. Selim M, Fink J, Linfante I, Kumar S, Schlaug G, Caplan LR. Diagnosis of cerebral venous thrombosis with echo-planar T2\*-weighted magnetic resonance imaging. *Arch Neurol.* 2002;59:1021–1026.
  120. Bianchi D, Maeder P, Bogousslavsky J, Schnyder P, Meuli RA. Diagnosis of cerebral venous thrombosis with routine magnetic resonance: an update. *Eur Neurol.* 1998;40:179–190.
  121. Casey SO, Alberico RA, Patel M, Jimenez JM, Ozsvath RR, Maguire WM, Taylor ML. Cerebral CT venography. *Radiology.* 1996;198:163–170.
  122. Corvol JC, Oppenheim C, Manai R, Logak M, Dormont D, Samson Y, Marsault C, Rancurel G. Diffusion-weighted magnetic resonance imaging in a case of cerebral venous thrombosis. *Stroke.* 1998;29:2649–2652.
  123. Hsu LC, Lirng JF, Fuh JL, Wang SJ, Shyu HY, Liu HC. Proton magnetic resonance spectroscopy in deep cerebral venous thrombosis. *Clin Neurol Neurosurg.* 1998;100:27–30.
  124. Keller E, Flacke S, Urbach H, Schild HH. Diffusion- and perfusion-weighted magnetic resonance imaging in deep cerebral venous thrombosis. *Stroke.* 1999;30:1144–1146.
  125. Lafitte F, Boukobza M, Guichard JP, Hoeffel C, Reizine D, Ille O, Woimant F, Merland JJ. MRI and MRA for diagnosis and follow-up of cerebral venous thrombosis (CVT). *Clin Radiol.* 1997;52:672–679.
  126. Röther J, Waggie K, van Bruggen N, de Crespigny AJ, Moseley ME. Experimental cerebral venous thrombosis: evaluation using magnetic resonance imaging. *J Cereb Blood Flow Metab.* 1996;16:1353–1361.
  127. Wang AM. MRA of venous sinus thrombosis. *Clin Neurosci.* 1997;4:158–164.
  128. Yuh WT, Simonson TM, Wang AM, Koci TM, Tali ET, Fisher DJ, Simon JH, Jinkins JR, Tsai F. Venous sinus occlusive disease: MR findings. *AJNR Am J Neuroradiol.* 1994;15:309–316.
  129. Meckel S, Reisinger C, Bremerich J, Damm D, Wolbers M, Engelter S, Scheffler K, Wetzel SG. Cerebral venous thrombosis: diagnostic accuracy of combined, dynamic and static, contrast-enhanced 4D MR. *AJNR Am J Neuroradiol.* 2010;31:527–535.
  130. Doege CA, Tavakolian R, Kerskens CM, Romero BI, Lehmann R, Einhüpfel KM, Villringer A. Perfusion and diffusion magnetic resonance imaging in human cerebral venous thrombosis. *J Neurol.* 2001;248:564–571.
  131. Ducreux D, Oppenheim C, Vandamme X, Dormont D, Samson Y, Rancurel G, Cosnard G, Marsault C. Diffusion-weighted imaging patterns of brain damage associated with cerebral venous thrombosis. *AJNR Am J Neuroradiol.* 2001;22:261–268.
  132. Lövblad KO, Bassetti C, Schneider J, Guzman R, El-Koussy M, Remonda L, Schroth G. Diffusion-weighted MR in cerebral venous thrombosis. *Cerebrovasc Dis.* 2001;11:169–176.
  133. Yoshikawa T, Abe O, Tsuchiya K, Okubo T, Tobe K, Masumoto T, Hayashi N, Mori H, Yamada H, Aoki S, Ohtomo K. Diffusion-weighted magnetic resonance imaging of dural sinus thrombosis. *Neuroradiology.* 2002;44:481–488.
  134. Liauw L, van Buchem MA, Spilt A, de Bruijn FT, van den Berg R, Hermans J, Wasser MN. MR angiography of the intracranial venous system. *Radiology.* 2000;214:678–682.
  135. Chu K, Kang DW, Yoon BW, Roh JK. Diffusion-weighted magnetic resonance in cerebral venous thrombosis. *Arch Neurol.* 2001;58:1569–1576.
  136. Ferro JM, Correia M, Pontes C, Baptista MV, Pita F; Cerebral Venous Thrombosis Portuguese Collaborative Study Group (Venoport). Cerebral vein and dural sinus thrombosis in Portugal: 1980–1998. *Cerebrovasc Dis.* 2001;11:177–182.
  137. Dormont D, Sag K, Biondi A, Wechsler B, Marsault C. Gadolinium-enhanced MR of chronic dural sinus thrombosis. *AJNR Am J Neuroradiol.* 1995;16:1347–1352.
  138. Forbes KP, Pipe JG, Heiserman JE. Evidence for cytotoxic edema in the pathogenesis of cerebral venous infarction. *AJNR Am J Neuroradiol.* 2001;22:450–455.
  139. Ferro JM, Canhão P. Acute treatment of cerebral venous and dural sinus thrombosis. *Curr Treat Options Neurol.* 2008;10:126–137.
  140. Widjaja E, Griffiths PD. Intracranial MR in children: normal anatomy and variations. *AJNR Am J Neuroradiol.* 2004;25:1557–1562.
  141. Suzuki Y, Ikeda H, Shimadu M, Ikeda Y, Matsumoto K. Variations of the basal vein: identification using three-dimensional CT angiography. *AJNR Am J Neuroradiol.* 2001;22:670–676.
  142. Hu HH, Campeau NG, Huston J 3rd, Kruger DG, Haider CR, Riederer SJ. High-spatial-resolution contrast-enhanced MR angiography of the

- intracranial venous system with fourfold accelerated two-dimensional sensitivity encoding. *Radiology*. 2007;243:853–861.
143. Idbah A, Boukobza M, Crassard I, Porcher R, Bousser MG, Chabriat H. MRI of clot in cerebral venous thrombosis: high diagnostic value of susceptibility-weighted images. *Stroke*. 2006;37:991–995.
  144. Farb RI, Scott JN, Willinsky RA, Montanera WJ, Wright GA, terBrugge KG. Intracranial venous system: gadolinium-enhanced three-dimensional MR venography with auto-triggered elliptic centric-ordered sequence: initial experience. *Radiology*. 2003;226:203–209.
  145. Kirchhof K, Welzel T, Jansen O, Sartor K. More reliable noninvasive visualization of the cerebral veins and dural sinuses: comparison of three MR angiographic techniques. *Radiology*. 2002;224:804–810.
  146. Liang L, Korogi Y, Sugahara T, Onomichi M, Shigematsu Y, Yang D, Kitajima M, Hiai Y, Takahashi M. Evaluation of the intracranial dural sinuses with a 3D contrast-enhanced MP-RAGE sequence: prospective comparison with 2D-TOF MR venography and digital subtraction angiography. *AJNR Am J Neuroradiol*. 2001;22:481–492.
  147. Isensee C, Reul J, Thron A. Magnetic resonance imaging of thrombosed dural sinuses. *Stroke*. 1994;25:29–34.
  148. Lewin JS, Masaryk TJ, Smith AS, Ruggieri PM, Ross JS. Time-of-flight intracranial MR venography: evaluation of the sequential oblique section technique. *AJNR Am J Neuroradiol*. 1994;15:1657–1664.
  149. Vogl TJ, Bergman C, Villringer A, Einhäupl K, Lissner J, Felix R. Dural sinus thrombosis: value of venous MR angiography for diagnosis and follow-up. *AJR Am J Roentgenol*. 1994;162:1191–1198.
  150. Wasenko JJ, Holsapple JW, Winfield JA. Cerebral venous thrombosis: demonstration with magnetic resonance angiography. *Clin Imaging*. 1995;19:153–161.
  151. Rizzo L, Crasto SG, Rudà R, Gallo G, Tola E, Garabello D, De Lucchi R. Cerebral venous thrombosis: role of CT, MRI and MRA in the emergency setting. *Radiol Med*. 2010;115:313–325.
  152. Hsu HY, Wang PY, Chen CC, Hu HH. Dural arteriovenous fistula after cerebral sinus thrombosis: a case study of serial venous transcranial color-coded sonography. *J Ultrasound Med*. 2004;23:1095–1100.
  153. Leach JL, Strub WM, Gaskill-Shiple MF. Cerebral venous thrombus signal intensity and susceptibility effects on gradient recalled-echo MR imaging. *AJNR Am J Neuroradiol*. 2007;28:940–945.
  154. Komiyama M, Ishiguro T, Kitano S, Sakamoto H, Nakamura H. Serial antenatal sonographic observation of cerebral dural sinus malformation. *AJNR Am J Neuroradiol*. 2004;25:1446–1448.
  155. Schwartz N, Monteaugudo A, Bornstein E, Timor-Tritsch IE, Zagzag D, Kudla M. Thrombosis of an ectatic torcular herophilii: anatomic localization using fetal neurosonography. *J Ultrasound Med*. 2008;27:989–991.
  156. Schaller B, Graf R, Sanada Y, Tolnay M, Rosner G, Wienhard K, Heiss WD. Hemodynamic changes after occlusion of the posterior superior sagittal sinus: an experimental PET study in cats. *AJNR Am J Neuro-radiol*. 2003;24:1876–1880.
  157. Kawai N, Shindou A, Masada T, Tamiya T, Nagao S. Hemodynamic and metabolic changes in a patient with cerebral venous sinus thrombosis: evaluation using O-15 positron emission tomography. *Clin Nucl Med*. 2005;30:391–394.
  158. Liang L, Korogi Y, Sugahara T, Ikushima I, Shigematsu Y, Takahashi M, Provenzale JM. Normal structures in the intracranial dural sinuses: delineation with 3D contrast-enhanced magnetization prepared rapid acquisition gradient-echo imaging sequence. *AJNR Am J Neuroradiol*. 2002;23:1739–1746.
  159. Zouaoui A, Hidden G. Cerebral venous sinuses: anatomical variants or thrombosis? *Acta Anat (Basel)*. 1988;133:318–324.
  160. Ayanzen RH, Bird CR, Keller PJ, McCully FJ, Theobald MR, Heiserman JE. Cerebral MR venography: normal anatomy and potential diagnostic pitfalls. *AJNR Am J Neuroradiol*. 2000;21:74–78.
  161. Stam J, De Bruijn SF, DeVeber G. Anticoagulation for cerebral sinus thrombosis. *Cochrane Database Syst Rev*. 2002;(4):CD002005.
  162. Rice D, Swisher S, Pisters K, Fossella F, Herbst R, Hofstetter W, Kies M, Komaki R, Lippman S, Mehran R, Roth J, Stewart D, Vaporciyan A, Walsh G, Cox J. Comment on “Treatment of non-small cell lung cancer stage IIIA: ACCP evidence-based clinical practice guidelines (2nd edition).” *Chest*. 2008;134:1349, author reply 1350.
  163. Dunn W, Murphy JG. Simulation: about safety, not fantasy. *Chest*. 2008;133:6–9.
  164. Einhäupl K, Bousser MG, de Bruijn SF, Ferro JM, Martinelli I, Masuhr F, Stam J. EFNS guideline on the treatment of cerebral venous and sinus thrombosis. *Eur J Neurol*. 2006;13:553–559.
  165. Adams HP Jr, del Zoppo G, Alberts MJ, Bhatt DL, Brass L, Furlan A, Grubb RL, Higashida RT, Jauch EC, Kidwell C, Lyden PD, Morgenstern LB, Qureshi AI, Rosenwasser RH, Scott PA, Wijdicks EF. Guidelines for the early management of adults with ischemic stroke: a guideline from the American Heart Association/American Stroke Association Stroke Council, Clinical Cardiology Council, Cardiovascular Radiology and Intervention Council, and the Atherosclerotic Peripheral Vascular Disease and Quality of Care Outcomes in Research Interdisciplinary Working Groups [published correction appears in *Stroke*. 2007;38:e38 and *Stroke*. 2007;38:e96]. *Stroke*. 2007;38:1655–1711.
  166. Stroke Unit Trialists’ Collaboration. Organised inpatient (stroke unit) care for stroke. *Cochrane Database Syst Rev*. 2007 Oct 17;(4):CD000197.
  167. Stroke Unit Trialists’ Collaboration. How do stroke units improve patient outcomes? A collaborative systematic review of the randomized trials. *Stroke Unit Trialists Collaboration*. *Stroke*. 1997;28:2139–2144.
  168. Saposnik G, Fang J, O’Donnell M, Hachinski V, Kapral MK, Hill MD; Investigators of the Registry of the Canadian Stroke Network (RCSN) for the Stroke Outcome Research Canada (SORCan) Working Group. Escalating levels of access to in-hospital care and stroke mortality. *Stroke*. 2008;39:2522–2530.
  169. Saposnik G, Kapral MK, Coutts SB, Fang J, Demchuk AM, Hill MD; Investigators of the Registry of the Canadian Stroke Network (RCSN) for the Stroke Outcome Research Canada (SORCan) Working Group. Do all age groups benefit from organized inpatient stroke care? *Stroke*. 2009;40:3321–3327.
  170. Smith EE, Hassan KA, Fang J, Selchen D, Kapral MK, Saposnik G; Registry of the Canadian Stroke Network (RCSN); Stroke Outcome Research Canada (SORCan) Working Group. Do all ischemic stroke subtypes benefit from organized inpatient stroke care? *Neurology*. 2010;75:456–462.
  171. Einhäupl KM, Villringer A, Meister W, Mehraein S, Garner C, Pellkofer M, Haberbil RL, Pfister HW, Schmiedek P. Heparin treatment in sinus venous thrombosis [published correction appears in *Lancet*. 1991;338:958]. *Lancet*. 1991;338:597–600.
  172. de Bruijn SF, Stam J. Randomized, placebo-controlled trial of anticoagulant treatment with low-molecular-weight heparin for cerebral sinus thrombosis. *Stroke*. 1999;30:484–488.
  173. de Bruijn SF, Budde M, Teunisse S, de Haan RJ, Stam J. Long-term outcome of cognition and functional health after cerebral venous sinus thrombosis. *Neurology*. 2000;54:1687–1689.
  174. Daif A, Awada A, al-Rajeh S, Abduljabbar M, al Tahan AR, Obeid T, Malibry T. Cerebral venous thrombosis in adults: a study of 40 cases from Saudi Arabia. *Stroke*. 1995;26:1193–1195.
  175. Preter M, Tzourio C, Ameri A, Bousser MG. Long-term prognosis in cerebral venous thrombosis: follow-up of 77 patients. *Stroke*. 1996;27:243–246.
  176. Maqueda VM, Thijs V. Risk of thromboembolism after cerebral venous thrombosis. *Eur J Neurol*. 2006;13:302–305.
  177. Breteau G, Mounier-Vehier F, Godefroy O, Gauvrit JY, Mackowiak-Cordoliani MA, Girot M, Bertheloot D, Hénon H, Lucas C, Leclerc X, Fourrier F, Pruvo JP, Leys D. Cerebral venous thrombosis 3-year clinical outcome in 55 consecutive patients. *J Neurol*. 2003;250:29–35.
  178. Cakmak S, Derex L, Berruyer M, Nighoghossian N, Philippeau F, Adeleine P, Hermier M, Froment JC, Trouillas P. Cerebral venous thrombosis: clinical outcome and systematic screening of prothrombotic factors. *Neurology*. 2003;60:1175–1178.
  179. Stolz E, Rahimi A, Gerriets T, Kraus J, Kaps M. Cerebral venous thrombosis: an all or nothing disease? Prognostic factors and long-term outcome. *Clin Neurol Neurosurg*. 2005;107:99–107.
  180. Mak W, Mok KY, Tsoi TH, Cheung RT, Ho SL, Chang CM. Cerebral venous thrombosis in Hong Kong. *Cerebrovasc Dis*. 2001;11:282–283.
  181. Brucker AB, Vollert-Rogenhofer H, Wagner M, Stieglbauer K, Felber S, Trenkler J, Deisenhammer E, Aichner F. Heparin treatment in acute cerebral sinus venous thrombosis: a retrospective clinical and MR analysis of 42 cases. *Cerebrovasc Dis*. 1998;8:331–337.
  182. Nagaraja D, Rao BSS, Taly AB. Randomized controlled trial of heparin in therapy of cerebral venous/sinus thrombosis. *Nimhans J*. 1995;13:111–115.
  183. Ameri A, Bousser MG. Cerebral venous thrombosis. *Neurol Clin*. 1992;10:87–111.
  184. van Dongen CJ, van den Belt AG, Prins MH, Lensing AW. Fixed dose subcutaneous low molecular weight heparins versus adjusted dose unfractionated heparin for venous thromboembolism. *Cochrane Database Syst Rev*. 2004 Oct 18;(4):CD001100.



185. Masuhr F, Einhüpl K. Treatment of cerebral venous and sinus thrombosis. *Front Neurol Neurosci*. 2008;23:132–143.
186. Röttger C, Trittmacher S, Gerriets T, Blaes F, Kaps M, Stolz E. Reversible MR imaging abnormalities following cerebral venous thrombosis. *AJNR Am J Neuroradiol*. 2005;26:607–613.
187. Sébire G, Tabarki B, Saunders DE, Leroy I, Liesner R, Saint-Martin C, Husson B, Williams AN, Wade A, Kirkham FJ. Cerebral venous sinus thrombosis in children: risk factors, presentation, diagnosis and outcome. *Brain*. 2005;128(part 3):477–489.
188. Boussier MG. Cerebral venous thrombosis: nothing, heparin, or local thrombolysis? *Stroke*. 1999;30:481–483.
189. Frey JL, Muro GJ, McDougall CG, Dean BL, Jahnke HK. Cerebral venous thrombosis: combined intrathrombus rtPA and intravenous heparin. *Stroke*. 1999;30:489–494.
190. Mehraein S, Schmidt K, Villringer A, Valdueza JM, Masuhr F. Heparin treatment in cerebral sinus and venous thrombosis: patients at risk of fatal outcome. *Cerebrovasc Dis*. 2003;15:17–21.
191. Stam J, de Bruijn S, deVeber G. Anticoagulation for cerebral sinus thrombosis. *Stroke*. 2003;34:1054–1055.
192. Stolz E, Trittmacher S, Rahimi A, Gerriets T, Röttger C, Siekmann R, Kaps M. Influence of recanalization on outcome in dural sinus thrombosis: a prospective study. *Stroke*. 2004;35:544–547.
193. Baumgartner RW, Studer A, Arnold M, Georgiadis D. Recanalisation of cerebral venous thrombosis. *J Neurol Neurosurg Psychiatry*. 2003;74:459–461.
194. Strupp M, Covi M, Seelos K, Dichgans M, Brandt T. Cerebral venous thrombosis: correlation between recanalization and clinical outcome: a long-term follow-up of 40 patients. *J Neurol*. 2002;249:1123–1124.
195. Bagley LJ, Hurst RW, Galetta S, Teener J, Sinson GP. Use of a microsnare to aid direct thrombolytic therapy of dural sinus thrombosis. *AJR Am J Roentgenol*. 1998;170:784–786.
196. Canevini MP, De Sarro G, Galimberti CA, Gatti G, Licchetta L, Malerba A, Muscas G, La Neve A, Striano P, Perucca E; SOPHIE Study Group. Relationship between adverse effects of antiepileptic drugs, number of coprescribed drugs, and drug load in a large cohort of consecutive patients with drug-refractory epilepsy. *Epilepsia*. 2010;51:797–804.
197. Ferro JM, Canhão P, Boussier MG, Stam J, Barinagarrementeria F; ISCVT Investigators. Early seizures in cerebral vein and dural sinus thrombosis: risk factors and role of antiepileptics. *Stroke*. 2008;39:1152–1158.
198. Boussier MG, Russell RR. Pathology and pathogenesis of venous infarction. In: Boussier MG, ed. *Cerebral Venous Thrombosis*. Paris VI Univ, Paris, France: WB Saunders Company; 1997:20–21.
199. Hanley DF, Feldman E, Borel CO, Rosenbaum AE, Goldberg AL. Treatment of sagittal sinus thrombosis associated with cerebral hemorrhage and intracranial hypertension. *Stroke*. 1988;19:903–909.
200. Keller E, Pangalu A, Fandino J, Köni D, Yonekawa Y. Decompressive craniectomy in severe cerebral venous and dural sinus thrombosis. *Acta Neurochir Suppl*. 2005;94:177–183.
201. Kersbergen KJ, de Vries LS, van Straaten HL, Benders MJ, Nievelstein RA, Groenendaal F. Anticoagulation therapy and imaging in neonates with a unilateral thalamic hemorrhage due to cerebral sinovenous thrombosis. *Stroke*. 2009;40:2754–2760.
202. Lanterna LA, Griitti P, Manara O, Grimald G, Bortolotti G, Biroli F. Decompressive surgery in malignant dural sinus thrombosis: report of 3 cases and review of the literature. *Neurosurg Focus*. 2009;26:E5.
203. Stefani R, Latronico N, Cornali C, Rasulo F, Bollati A. Emergent decompressive craniectomy in patients with fixed dilated pupils due to cerebral venous and dural sinus thrombosis: report of three cases. *Neurosurgery*. 1999;45:626–629.
204. Vahedi K, Hofmeijer J, Juettler E, Vicaut E, George B, Algra A, Amelink GJ, Schmiedek P, Schwab S, Rothwell PM, Boussier MG, van der Worp HB, Hacke W; DECIMAL, DESTINY, and HAMLET Investigators. Early decompressive surgery in malignant infarction of the middle cerebral artery: a pooled analysis of three randomised controlled trials. *Lancet Neurol*. 2007;6:215–222.
205. Wu YW, Hamrick SE, Miller SP, Haward MF, Lai MC, Callen PW, Barkovich AJ, Ferriero DM. Intraventricular hemorrhage in term neonates caused by sinovenous thrombosis. *Ann Neurol*. 2003;54:123–126.
206. Canhão P, Falcão F, Ferro JM. Thrombolytics for cerebral sinus thrombosis: a systematic review. *Cerebrovasc Dis*. 2003;15:159–166.
207. Chaloupka JC, Mangla S, Huddle DC. Use of mechanical thrombolysis via microballoon percutaneous transluminal angioplasty for the treatment of acute dural sinus thrombosis: case presentation and technical report. *Neurosurgery*. 1999;45:650–656.
208. Stam J, Majoie CB, van Delden OM, van Lienden KP, Reekers JA. Endovascular thrombectomy and thrombolysis for severe cerebral sinus thrombosis: a prospective study. *Stroke*. 2008;39:1487–1490.
209. Messé SR, Sansing LH, Cucchiara BL, Herman ST, Lyden PD, Kasner SE; CHANT Investigators. Prophylactic antiepileptic drug use is associated with poor outcome following ICH. *Neurocrit Care*. 2009;11:38–44.
210. Marinelli I, Bucciarelli P, Passamonti SM, Battaglioli T, Previtali E, Mannucci PM. Long-term evaluation of the risk of recurrence after cerebral sinus-venous thrombosis. *Circulation*. 2010;121:2740–2746.
211. Wysokinska EM, Wysokinski WE, Brown RD, Karnicki K, Gosk-Beirska I, Grill D, McBane RD 2nd. Thrombophilia differences in cerebral venous sinus and lower extremity deep venous thrombosis. *Neurology*. 2008;70:627–633.
212. Choulakian A, Alexander MJ. Mechanical thrombectomy with the penumbra system for treatment of venous sinus thrombosis. *J NeuroIntervent Surg*. 2010;2:153–156.
213. Persson L, Lilja A. Extensive dural sinus thrombosis treated by surgical removal and local streptokinase infusion. *Neurosurgery*. 1990;26:117–121.
214. Ekseth K, Boström S, Vegfors M. Reversibility of severe sagittal sinus thrombosis with open surgical thrombectomy combined with local infusion of tissue plasminogen activator: technical case report. *Neurosurgery*. 1998;43:960–965.
215. Coutinho JM, Majoie CB, Coert BA, Stam J. Decompressive hemicraniectomy in cerebral sinus thrombosis: consecutive case series and review of the literature. *Stroke*. 2009;40:2233–2235.
216. Canhão P, Cortesão A, Cabral M, Ferro JM, Stam J, Boussier MG, Barinagarrementeria F; ISCVT Investigators. Are steroids useful to treat cerebral venous thrombosis? *Stroke*. 2008;39:105–110.
217. Masuhr F, Busch M, Amberger N, Ortwein H, Weih M, Neumann K, Einhüpl K, Mehraein S. Risk and predictors of early epileptic seizures in acute cerebral venous and sinus thrombosis. *Eur J Neurol*. 2006;13:852–856.
218. Ferro JM, Correia M, Rosas MJ, Pinto AN, Neves G; Cerebral Venous Thrombosis Portuguese Collaborative Study Group (Venoport). Seizures in cerebral vein and dural sinus thrombosis. *Cerebrovasc Dis*. 2003;15:78–83.
219. Miranda B, Ferro JM, Canhão P, Stam J, Boussier MG, Barinagarrementeria F, Scoditti U; ISCVT Investigators. Venous thromboembolic events after cerebral vein thrombosis. *Stroke*. 2010;41:1901–1906.
220. Kearon C, Kahn SR, Agnelli G, Goldhaber S, Raskob GE, Comerota AJ. Antithrombotic therapy for venous thromboembolic disease: American College of Chest Physicians Evidence-Based Clinical Practice Guidelines (8th Edition) [published correction appears in *Chest*. 2008;134:892]. *Chest*. 2008;133(suppl):454S–545S.
221. Lijfering WM, Brouwer JL, Veeger NJ, Bank I, Coppens M, Middeldorp S, Hamulyák K, Prins MH, Büller HR, van der Meer J. Selective testing for thrombophilia in patients with first venous thrombosis: results from a retrospective family cohort study on absolute thrombotic risk for currently known thrombophilic defects in 2479 relatives. *Blood*. 2009;113:5314–5322.
222. Mackie I, Cooper P, Kitchen S. Quality assurance issues and interpretation of assays. *Semin Hematol*. 2007;44:114–125.
223. Goodwin AJ, Rosendaal FR, Kottke-Marchant K, Bovill EG. A review of the technical, diagnostic, and epidemiologic considerations for protein S assays. *Arch Pathol Lab Med*. 2002;126:1349–1366.
224. Miyakis S, Lockshin MD, Atsumi T, Branch DW, Brey RL, Cervera R, Derksen RH, De Groot PG, Koike T, Meroni PL, Reber G, Shoenfeld Y, Tincani A, Vlachoyiannopoulos PG, Krilis SA. International consensus statement on an update of the classification criteria for definite antiphospholipid syndrome (APS). *J Thromb Haemost*. 2006;4:295–306.
225. Lim W, Crowther MA, Eikelboom JW. Management of antiphospholipid antibody syndrome: a systematic review. *JAMA*. 2006;295:1050–1057.
226. Asherson RA, Cervera R, de Groot PG, Erkan D, Boffa MC, Piette JC, Khamashta MA, Shoenfeld Y; Catastrophic Antiphospholipid Syndrome Registry Project Group. Catastrophic antiphospholipid syndrome: international consensus statement on classification criteria and treatment guidelines. *Lupus*. 2003;12:530–534.
227. Schulman S, Svenungsson E, Granqvist S; Duration of Anticoagulation Study Group. Anticardiolipin antibodies predict early recurrence of

- thromboembolism and death among patients with venous thromboembolism following anticoagulant therapy. *Am J Med.* 1998;104:332–338.
228. Kearon C, Gent M, Hirsh J, Weitz J, Kovacs MJ, Anderson DR, Turpie AG, Green D, Ginsberg JS, Wells P, MacKinnon B, Julian JA. A comparison of three months of anticoagulation with extended anticoagulation for a first episode of idiopathic venous thromboembolism [published correction appears in *N Engl J Med.* 1999;341:298]. *N Engl J Med.* 1999;340:901–907.
  229. Shrivastava S, Ridker PM, Glynn RJ, Goldhaber SZ, Moll S, Bounameaux H, Bauer KA, Kessler CM, Cushman M. D-dimer, factor VIII coagulant activity, low-intensity warfarin and the risk of recurrent venous thromboembolism. *J Thromb Haemost.* 2006;4:1208–1214.
  230. Palareti G, Legnani C, Cosmi B, Valdré L, Lunghi B, Bernardi F, Coccheri S. Predictive value of D-dimer test for recurrent venous thromboembolism after anticoagulation withdrawal in subjects with a previous idiopathic event and in carriers of congenital thrombophilia. *Circulation.* 2003;108:313–318.
  231. Palareti G, Cosmi B, Legnani C, Tosi A, Brusi C, Iorio A, Pengo V, Ghirarduzzi A, Pattacini C, Testa S, Lensing AW, Tripodi A; PROLONG Investigators. D-dimer testing to determine the duration of anticoagulation therapy [published correction appears in *N Engl J Med.* 2006;355:2797]. *N Engl J Med.* 2006;355:1780–1789.
  232. Wakai A, Gleeson A, Winter D. Role of fibrin D-dimer testing in emergency medicine. *Emerg Med J.* 2003;20:319–325.
  233. Buccino G, Scoditti U, Patteri I, Bertolino C, Mancina D. Neurological and cognitive long-term outcome in patients with cerebral venous sinus thrombosis. *Acta Neurol Scand.* 2003;107:330–335.
  234. Ferro JM, Vasconcelos J, Canhão P, Bousser MG, Stam J, Barinagarrementeria F; ISCVT Investigators. Remote seizures in acute cerebral vein and dural sinus thrombosis (CVT): incidence and associated conditions. *Cerebrovasc Dis.* 2007;23(suppl 2):48. Abstract.
  235. Ferro JM, Canhão P, Stam J, Bousser MG, Barinagarrementeria F, Massaro A, Ducrocq X, Kasner SE; ISCVT Investigators. Delay in the diagnosis of cerebral vein and dural sinus thrombosis: influence on outcome. *Stroke.* 2009;40:3133–3138.
  236. Phatourous CC, Halbach VV, Dowd CF, Lempert TE, Malek AM, Meyers PM, Higashida RT. Acquired pial arteriovenous fistula following cerebral vein thrombosis. *Stroke.* 1999;30:2487–2490.
  237. Kenet G, Waldman D, Lubetsky A, Kornbrut N, Khalil A, Koren A, Wolach B, Fattal A, Kapelushnik J, Tamary H, Yacobovitch J, Raveh E, Revel-Vilk S, Toren A, Brenner B. Paediatric cerebral sinus vein thrombosis: a multi-center, case-controlled study. *Thromb Haemost.* 2004;92:713–718.
  238. François P, Fabre M, Lioret E, Jan M. Vascular cerebral thrombosis during pregnancy and post-partum [in French]. *Neurochirurgie.* 2000;46:105–109.
  239. Lanska DJ, Kryscio RJ. Peripartum stroke and intracranial venous thrombosis in the National Hospital Discharge Survey. *Obstet Gynecol.* 1997;89:413–418.
  240. Wilterdink JL, Easton JD. Cerebral ischemia in pregnancy. *Adv Neurol.* 2002;90:51–62.
  241. Jeng JS, Tang SC, Yip PK. Incidence and etiologies of stroke during pregnancy and puerperium as evidenced in Taiwanese women. *Cerebrovasc Dis.* 2004;18:290–295.
  - 241a. Bates SM, Greer IA, Pabinger I, Sofaer S, Hirsh J. Venous thromboembolism, thrombophilia, antithrombotic therapy, and pregnancy: American College of Chest Physicians Evidence-Based Clinical Practice Guidelines (8th Edition). *Chest.* 2008;133(suppl):844S–886S.
  242. Ni Ainle F, Wong A, Appleby N, Byrne B, Regan C, Hassan T, Milner M, Sullivan AO, White B, O'Donnell J. Efficacy and safety of once daily low molecular weight heparin (tinzaparin sodium) in high risk pregnancy. *Blood Coagul Fibrinolysis.* 2008;19:689–692.
  243. Niwa J, Ohyama H, Matumura S, Maeda Y, Shimizu T. Treatment of acute superior sagittal sinus thrombosis by t-PA infusion via venography: direct thrombolytic therapy in the acute phase. *Surg Neurol.* 1998;49:425–429.
  244. López JA, Kearon C, Lee AY. Deep venous thrombosis. *Hematology Am Soc Hematol Educ Program.* 2004:439–456.
  245. Kenet G, Kirkham F, Niederstadt T, Heinecke A, Saunders D, Stoll M, Brenner B, Bidlingmaier C, Heller C, Knöfler R, Schobess R, Zieger B, Sébire G, Nowak-Göttl U; European Thromboses Study Group. Risk factors for recurrent venous thromboembolism in the European collaborative paediatric database on cerebral venous thrombosis: a multicentre cohort study. *Lancet Neurol.* 2007;6:595–603.
  246. Lamy C, Hamon JB, Coste J, Mas JL; French Study Group on Stroke in Pregnancy. Ischemic stroke in young women: risk of recurrence during subsequent pregnancies. *Neurology.* 2000;55:269–274.
  247. Mehraein S, Ortwein H, Busch M, Weih M, Einhäupl K, Masuhr F. Risk of recurrence of cerebral venous and sinus thrombosis during subsequent pregnancy and puerperium. *J Neurol Neurosurg Psychiatry.* 2003;74:814–816.
  248. Srinivasan K. Cerebral venous and arterial thrombosis in pregnancy and puerperium: a study of 135 patients. *Angiology.* 1983;34:731–746.
  249. Barnes C, Newall F, Furmedge J, Mackay M, Monagle P. Cerebral sinus venous thrombosis in children. *J Paediatr Child Health.* 2004;40:53–55.
  250. Kenet G, Lütthoff LK, Albisetti M, Bernard T, Bonduel M, Brandao L, Chabrier S, Chan A, deVeber G, Fiedler B, Fullerton HJ, Goldenberg NA, Grabowski E, Günther G, Heller C, Holzhauser S, Iorio A, Journeycake J, Junker R, Kirkham FJ, Kurnik K, Lynch JK, Male C, Manco-Johnson M, Mesters R, Monagle P, van Ommen CH, Raffini L, Rostásy K, Simioni P, Sträter RD, Young G, Nowak-Göttl U. Impact of thrombophilia on risk of arterial ischemic stroke or cerebral sinus venous thrombosis in neonates and children: a systematic review and meta-analysis of observational studies. *Circulation.* 2010;121:1838–1847.
  251. Simchen MJ, Goldstein G, Lubetsky A, Strauss T, Schiff E, Kenet G. Factor V Leiden and antiphospholipid antibodies in either mothers or infants increase the risk for perinatal arterial ischemic stroke. *Stroke.* 2009;40:65–70.
  252. Wu YW, Miller SP, Chin K, Collins AE, Lomeli SC, Chuang NA, Barkovich AJ, Ferriero DM. Multiple risk factors in neonatal sinovenous thrombosis. *Neurology.* 2002;59:438–440.
  253. Fitzgerald KC, Williams LS, Garg BP, Carvalho KS, Golomb MR. Cerebral sinovenous thrombosis in the neonate. *Arch Neurol.* 2006;63:405–409.
  254. Maguire JL, deVeber G, Parkin PC. Association between iron-deficiency anemia and stroke in young children. *Pediatrics.* 2007;120:1053–1057.
  255. Shroff M, deVeber G. Sinovenous thrombosis in children. *Neuroimaging Clin N Am.* 2003;13:115–138.
  256. Widjaja E, Shroff M, Blaser S, Laughlin S, Raybaud C. 2D time-of-flight MR venography in neonates: anatomy and pitfalls. *AJNR Am J Neuroradiol.* 2006;27:1913–1918.
  257. Tsao PN, Lee WT, Peng SF, Lin JH, Yau KI. Power Doppler ultrasound imaging in neonatal cerebral venous sinus thrombosis. *Pediatr Neurol.* 1999;21:652–655.
  258. Volpe JJ. *Neurology of the Newborn.* Philadelphia, Pa: Saunders; 2001.
  259. Carvalho KS, Bodensteiner JB, Connolly PJ, Garg BP. Cerebral venous thrombosis in children. *J Child Neurol.* 2001;16:574–580.
  260. De Schryver EL, Blom I, Braun KP, Kappelle LJ, Rinkel GJ, Peters AC, Jennekens-Schinkel A. Long-term prognosis of cerebral venous sinus thrombosis in childhood. *Dev Med Child Neurol.* 2004;46:514–519.
  261. Azin H, Ashjzadeh N. Cerebral venous sinus thrombosis: clinical features, predisposing and prognostic factors. *Acta Neurol Taiwan.* 2008;17:82–87.
  262. Lobo SN, Bhargava B. Visual loss and associated ocular manifestations of cerebral venous thrombosis. *AIOC 2008 Proc.* 2008:360–361.
  263. Rousseaux M, Cabaret M, Bernati T, Pruvo JP, Steinling M. Residual deficit of verbal recall after a left internal cerebral vein infarct [in French]. *Rev Neurol (Paris).* 1998;154:401–407.
  264. Moharir M, Shroff M, Stephens D, Pontigon AM, Chan A, MacGregor D, Mikulis D, Adams M, deVeber G. Anticoagulants in pediatric cerebral sinovenous thrombosis: a safety and outcome study. *Ann Neurol.* 2010;67:590–599.
  265. International Pediatric Stroke Study Web database. <https://app3.ccb.sickkids.ca/estrokestudy/>. Accessed June 17, 2009.
  266. Golomb MR, Fullerton HJ, Nowak-Göttl U, DeVeber G; International Pediatric Stroke Study Group. Male predominance in childhood ischemic stroke: findings from the International Pediatric Stroke Study. *Stroke.* 2009;40:52–57.
  267. Roach ES, Golomb MR, Adams R, Biller J, Daniels S, DeVeber G, Ferriero D, Jones BV, Kirkham FJ, Scott RM, Smith ER. Management of stroke in infants and children: a scientific statement from a Special Writing Group of the American Heart Association Stroke Council and the Council on Cardiovascular Disease in the Young [published correction appears in *Stroke.* 2009;40:e8–e10]. *Stroke.* 2008;39:2644–2691.
  268. Paediatric Stroke Working Group. Stroke in childhood: clinical guidelines for diagnosis, management and rehabilitation, 2004.

- <http://www.rcplondon.ac.uk/pubs/books/childstroke/>. Accessed November 9, 2010.
269. Monagle P, Chalmers E, Chan A, DeVeber G, Kirkham F, Massicotte P, Michelson AD. Antithrombotic therapy in neonates and children: American College of Chest Physicians Evidence-Based Clinical Practice Guidelines (8th Edition). *Chest*. 2008;133(suppl):887S–68S.
  270. Bienfait HP, Stam J, Lensing AW, van Hilten JJ. Thrombosis of the cerebral veins and sinuses in 62 patients [in Dutch]. *Ned Tijdschr Geneeskd*. 1995;139:1286–1291.
  271. Lleó A, Martí-Fàbregas J, Guardia E, Martí-Vilalta JL. Cerebral venous thrombosis: study of 17 cases [in Spanish]. *Med Clin (Barc)*. 1999;113:537–540.
  272. Masuhr F, Mehraein S. Cerebral venous and sinus thrombosis: patients with a fatal outcome during intravenous dose-adjusted heparin treatment. *Neurocrit Care*. 2004;1:355–361.
  273. Stolz E, Kemkes-Matthes B, Pötsch B, Hahn M, Kraus J, Wirbartz A, Kaps M. Screening for thrombophilic risk factors among 25 German patients with cerebral venous thrombosis. *Acta Neurol Scand*. 2000;102:31–36.
  274. Yang J, Zhou JX, Zhou ZW, Li GL, Yang XS. Clinical features and prognosis of cerebral venous thrombosis [in Chinese]. *Zhong Nan Da Xue Xue Bao Yi Xue Ban*. 2008;33:365–368.
  275. Rondepierre P, Hamon M, Leys D, Leclerc X, Mounier-Vehier F, Godefroy O, Janssens E, Pruvo JP. Cerebral venous thromboses: study of the course [in French]. *Rev Neurol (Paris)*. 1995;151:100–104.
  276. Stolz E, Gerriets T, Bödeker RH, Hügens-Penzel M, Kaps M. Intracranial venous hemodynamics is a factor related to a favorable outcome in cerebral venous thrombosis. *Stroke*. 2002;33:1645–1650.
  277. de Bruijn SF, de Haan RJ, Stam J; for the Cerebral Venous Sinus Thrombosis Study Group. Clinical features and prognostic factors of cerebral venous sinus thrombosis in a prospective series of 59 patients. *J Neurol Neurosurg Psychiatry*. 2001;70:105–108.
  278. Crassard I, Canhão P, Ferro JM, Bousser MG, Barinagarrementeria F, Stam J. Neurological worsening in the acute phase of cerebral venous thrombosis in ISCVT (International Study on Cerebral Venous Thrombosis). *Cerebrovasc Dis*. 2003;16(suppl 4):60. Abstract.
  279. Diaz JM, Schiffman JS, Urban ES, Maccario M. Superior sagittal sinus thrombosis and pulmonary embolism: a syndrome rediscovered. *Acta Neurol Scand*. 1992;86:390–396.
  280. Vucic S, Lye T, Mackenzie RA. Neuropsychological manifestations in a case of bilateral thalamic infarction. *J Clin Neurosci*. 2003;10:238–242.
  281. Barinagarrementeria F, Carlos C, Arrendondo H. Aseptic cerebral venous thrombosis: proposed prognostic scale. *J Stroke Cerebrovasc Dis*. 1992;2:34–39.
  282. Ferro JM, Bacelar-Nicolau H, Rodrigues T, Bacelar-Nicolau L, Canhão P, Crassard I, Bousser MG, Dutra AP, Massaro A, Mackowiack-Cordiolani MA, Leys D, Fontes J, Stam J, Barinagarrementeria F; ISCVT and VENOPORT Investigators. Risk score to predict the outcome of patients with cerebral vein and dural sinus thrombosis. *Cerebrovasc Dis*. 2009;28:39–44.
  283. Dentali F, Gianni M, Crowther MA, Ageno W. Natural history of cerebral vein thrombosis: a systematic review. *Blood*. 2006;108:1129–1134.
  284. Koopman K, Uyttenboogaart M, Vroomen PC, van der Meer J, De Keyser J, Luijckx GJ. Development and validation of a predictive outcome score of cerebral venous thrombosis. *J Neurol Sci*. 2009;276:66–68.
  285. Furie KL, Kasner SE, Adams RJ, Albers GW, Bush RL, Fagan SC, Halperin JL, Johnston SC, Katzan I, Kernan WN, Mitchell PH, Ovbiagele B, Palesch YY, Sacco RL, Schwamm LH, Wassertheil-Smoller S, Turan TN, Wentworth D; Guidelines for the prevention of stroke in patients with stroke or transient ischemic attack: a guideline for healthcare professionals from the American Heart Association/American Stroke Association. *Stroke*. 2011;42:227–276.
  286. Reference deleted in proof.

# Stroke

JOURNAL OF THE AMERICAN HEART ASSOCIATION



## Diagnosis and Management of Cerebral Venous Thrombosis: A Statement for Healthcare Professionals From the American Heart Association/American Stroke Association

Gustavo Saposnik, Fernando Barinagarrementeria, Robert D. Brown, Jr, Cheryl D. Bushnell, Brett Cucchiara, Mary Cushman, Gabrielle deVeber, Jose M. Ferro and Fong Y. Tsai

*Stroke*. 2011;42:1158-1192; originally published online February 3, 2011;  
doi: 10.1161/STR.0b013e31820a8364

*Stroke* is published by the American Heart Association, 7272 Greenville Avenue, Dallas, TX 75231  
Copyright © 2011 American Heart Association, Inc. All rights reserved.  
Print ISSN: 0039-2499. Online ISSN: 1524-4628

The online version of this article, along with updated information and services, is located on the World Wide Web at:

<http://stroke.ahajournals.org/content/42/4/1158>

Data Supplement (unedited) at:

<http://stroke.ahajournals.org/content/suppl/2012/03/12/STR.0b013e31820a8364.DC3>

<http://stroke.ahajournals.org/content/suppl/2012/02/28/STR.0b013e31820a8364.DC2>

<http://stroke.ahajournals.org/content/suppl/2012/02/28/STR.0b013e31820a8364.DC1>

**Permissions:** Requests for permissions to reproduce figures, tables, or portions of articles originally published in *Stroke* can be obtained via RightsLink, a service of the Copyright Clearance Center, not the Editorial Office. Once the online version of the published article for which permission is being requested is located, click Request Permissions in the middle column of the Web page under Services. Further information about this process is available in the [Permissions and Rights Question and Answer](#) document.

**Reprints:** Information about reprints can be found online at:  
<http://www.lww.com/reprints>

**Subscriptions:** Information about subscribing to *Stroke* is online at:  
<http://stroke.ahajournals.org/subscriptions/>

**Diagnóstico y tratamiento de la trombosis venosa cerebral. Comunicado de la *American Heart Association/American Stroke Association* para los profesionales de la salud**

---

El *Stroke Council on Epidemiology and Prevention* de la *American Heart Association* aborda por primera vez la realización de unas guías de práctica clínica para el diagnóstico y tratamiento de la trombosis venosa cerebral. Aunque se trata de un tipo poco frecuente de ictus (representando sólo el 0,5-1% del total), presenta unas características diferenciales importantes al afectar predominantemente a pacientes jóvenes y ser múltiples los factores de riesgo asociados a esta enfermedad. Se establecen recomendaciones basadas en la evidencia que abordan tanto los métodos diagnósticos de laboratorio y neuroimagen; las diferentes opciones terapéuticas, desde el tratamiento anticoagulante (con el uso de heparina en fase aguda) hasta nuevas alternativas en desarrollo como el tratamiento endovascular (trombectomía/trombolisis); y el manejo de las posibles complicaciones asociadas a la trombosis venosa cerebral, tanto las precoces (hidrocefalia, hipertensión intracraneal, crisis) como las tardías (recurrencias de trombosis venosa cerebral, cefalea, crisis, pérdida visual, fistula arteriovenosa). Por último, se analiza la evidencia disponible sobre el manejo de esta enfermedad en dos grupos poblacionales especialmente susceptibles: mujeres gestantes y niños. (Comentario al artículo *Diagnosis and Management of Cerebral Venous Thrombosis. A Statement for Healthcare professionals from the American Heart Association/American Stroke Association*. Gustavo Saposnik, Fernando Barinagarrementeria, Robert D. Brown, Jr, Cheryl D. Bushnell, Brett Cucchiara, Mary Cushman, Gabrielle deVeber, Jose M. Ferro, Fong Y. Tsai on behalf of the American Heart Association Stroke Council and the Council on Epidemiology and Prevention. *Stroke*. 2011;42:1158-1192.)

## AHA/ASA Scientific Statement

# 脳静脈血栓症の診断と管理

## Diagnosis and Management of Cerebral Venous Thrombosis

### A Statement for Healthcare Professionals From the American Heart Association/American Stroke Association

The American Academy of Neurology affirms the value of this statement as an educational tool for neurologists. The American Association of Neurological Surgeons and Congress of Neurological Surgeons have reviewed this document and affirm its educational content.

The Ibero-American Stroke Society (Sociedad Iberoamericana de Enfermedad Cerebrovascular) endorses the recommendations contained in this report.

Endorsed by the Society of NeuroInterventional Surgery

Gustavo Saposnik, MD, MSc, FAHA, Chair; Fernando Barinagarrementeria, MD, FAHA, FAAN; Robert D. Brown, Jr, MD, MPH, FAHA, FAAN; Cheryl D. Bushnell, MD, MHS, FAHA; Brett Cucchiara, MD, FAHA; Mary Cushman, MD, MSc, FAHA; Gabrielle deVeber, MD; Jose M. Ferro, MD, PhD; Fong Y. Tsai, MD; on behalf of the American Heart Association Stroke Council and the Council on Epidemiology and Prevention

Stroke 2011; 42: 1158-1192

筆者らは脳静脈洞血栓症 (cerebral venous sinus thrombosis : CVT) の診断, 管理, 治療に関する 1996 年から 2010 年 7 月までの文献を検討し, 米国心臓協会 (AHA) のエビデンスレベル (表 1) に基づいた推奨を提唱している。紙面の制限により, ここには主として管理と治療についての推奨しか掲載できないが, 小児科領域の治療に関する推奨は *Stroke* 日本語版 Vol.3, No.3, 2008 p32-37 に, 再発予防については *Stroke* 日本語版 Vol.5, No.4-S, 2010 も参照されたい。

### 脳静脈洞血栓症の疫学と危険因子

CVT は若年者に発症し, 発症率は 5 人 /100,000/ 年と推定され, 全脳卒中の 0.5 ~ 1.0% を占める。CVT には遺伝性または後天性の凝固亢進状態が存在する。遺伝性因子 (血栓性素因) には抗凝固蛋白欠乏症 (アンチトロンビン III, プロテイン C, プロテイン S), 第 5 凝固因子 Leiden 変異, プロトロンビン G20210A 変異が含まれている。高ホモシステイン血症と CVT の関連についてはまだ結論が得られていない。後天性因子 には手術, 外傷, 妊娠, 産褥, 抗リン脂質抗体症候群, 悪性腫瘍, ホルモン療法などがあり, 経口避妊薬 (OC) との関連も高く, 特にプロトロンビン G20210A 変異か第 5 凝固因子 Leiden 変異の保有者では OC によりリスクが極めて高くなる。幼少児では感染症が CVT の原因であることが多い。

### 脳静脈洞血栓症の臨床診断

CVT の臨床所見は頭蓋内圧亢進と脳実質の虚血 / 出血

によるが, 多くの場合両者が併存する。頭痛は 90% の症例にみられ, 頭痛に乳頭浮腫か複視 (外転神経麻痺) が併存すれば CVT を考慮すべきである。局所徴候としては片麻痺, 失語が多い。局所または全般性けいれん発作は約 40% にみられ, 脳深部静脈系では視床の損傷により, 局所症状なしに意識障害を発症することがある。臨床的に CVT を疑った場合, 血液検査ではプロトロンビン時間 (PT-INR) と活性化部分トロンボプラスチン時間 (aPTT) を測定し, 凝固亢進状態を起こし得る疾患と薬物を検索する必要がある (表 1: 推奨クラス I, エビデンス・レベル C)。脳脊髄液検査は髄膜炎の疑いがあるとき以外ではあまり有用でないが, 髄液圧の亢進は 80% にみられる。D-ダイマーは深部静脈血栓 (DVT) や肺塞栓 (PE) の除外には有用だが, D-ダイマー値が正常である場合, CVT の可能性は低いかもしれないが (表 1: 推奨クラス IIb, エビデンス・レベル B) 除外はできない。

### 脳静脈洞血栓症の画像診断 (表 2)

頭部 CT は頭痛やけいれん発作がある症例の検査の第一歩であるが, 造影なしでは診断感度は低い。上矢状静脈洞後方に血栓が形成されると高シグナル (high density : HD) 三角形がみられることがある (デルタサイン)。造影 CT では静脈や静脈洞内に血栓が造影欠損として認められ, 静脈洞に沿った硬膜の造影が増強される。MRI では静脈洞内の血栓が認められるが, 血栓形成後の時期により性状が異なる。CT 静脈造影 (CTV) は迅速かつ確実に CVT を描出するが, 隣接した骨により見にくい

場合がある。MR 静脈造影 (MRV)には二次元タイム・オブ・フライト法か造影 MRV が用いられる。グラディエント・エコーまたは磁化率強調画像では血栓のない洞形成不全は低シグナルを呈しない。造影 MRV では脳静脈構造がより鮮明になる。カテーテル脳血管撮影 (DSA)と脳静脈撮影は、MRV または CTV で結論がでない場合や血管内治療が考慮されている場合に施行される。脳静脈洞と皮質静脈の急性血栓症では脳静脈流の遅延が起こるが、DSA により脳静脈可視化の遅延が観察されるか、全く可視されないことがある。脳静脈撮影は内頸静脈からの造影剤の注入により施行され、通常は血管内治療中に行われる。

## 脳静脈洞血栓症の管理と治療 (表 3～5)

1) 急性期の管理と内科的治療 (表 3) : 脳卒中集中治療室 (SU)での徹底した管理により合併症が予防できると考えられる。急性期の抗凝固療法につき議論が続く理由は、CVT の診断がつく頃には出血性梗塞か脳内出血 (ICH) が起こっていることが多く、安全性が問題になるためである。無作為比較試験としては 2 件が造影画像で確認された CVT で施行されているが、そのうち 1 件は (*Lancet* 1991; 338: 597-600, *Lancet* 1991; 338: 958 [correction]) 20 例で未分画ヘパリン (UFH) と偽薬のポーラス (3000U) 後の持続点滴により活性化部分トロンボプラスチン時間 (aPTT) を治療前の 2 倍に延長させた。もう 1 件では (*Stroke* 1999; 30: 484-488), 59 例において低分子ヘパリン (LMWH) nadroparin (180 anti-Factor Xa units/kg/day 分 2 皮下注) と偽薬が 3 週間投与され、その後経口抗凝固薬が nadroparin 群のみに 3 カ月投与された。これら 2 件のメタ解析では、有意差ではなかったが、抗凝固薬群で死亡と要介助の相対的リスク (RR = 0.46) の低下が認められた。ICH を伴う CVT の抗凝固療法については、nadroparin を用いた試験で 29 例中 6 例が死亡したが、死亡は新規の出血や ICH の増大によるものではなかった。大規模観察研究である ISCVT 研究 (*Stroke* 2004; 35: 664-670) では、624 例中殆ど全例が初期に抗凝固療法を受けたが、16 カ月の死亡率は 8.3% で、79% に完治 (mRS 0～1) がみられ、10.4% に軽～中等度の障害 (mRS 2～3)、2.2% に重度の障害が残った。これらのデータは、治療前の ICH の有無にかかわらず、CVT における抗凝固療法を支持している。CVT では、aPTT で調整した未分画ヘパリンと低分子ヘパリンの優劣を示すデータはない。線溶療法 (fibrinolysis) は抗凝固療法によっても臨床的悪化や頭蓋内圧亢進がみられる場合に考慮される。ステロイド薬は血管原性浮腫を軽減させる役目があるが、凝固亢進状態を増進させる可能性がある。ISCVT 研究においては、ステロイドの使用で死亡率と要介助率が高くなる傾

向 (OR = 1.7) が示された。感染症と CVT が疑われる症例の治療には抗生物質による局所または全身性感染症の治療と感染源のドレナージを考慮すべきである。

2) 急性期の血管内・脳外科治療 (表 3) : カテーテル血栓溶解術では血栓の機械的な破壊と局所での線溶療法を行う。機械的血栓摘出術・血栓溶解術にはバルーン血栓摘出術と脳動脈血栓症に用いられる Merci リトリバーや Penumbra があり、局所線溶療法で効果が認められない静脈洞血栓に使い始められている。これらの血管内治療の有用性はまだ確立されていないが、もし抗凝固療法中の臨床的悪化、静脈性梗塞や ICH による圧排効果や頭蓋内圧亢進に対して標準的治療が効果しない場合に考慮しても良いだろう。脳外科的には、静脈性梗塞による著明な頭蓋内圧亢進には開頭減圧術が、重度の神経徴候を伴う大血腫には血腫除去術が必要となる場合がある。

3) 早期合併症の管理と予防 (表 4) : けいれん発作は成人の 37%、幼少児の 48%、新生児の 71% に発症するとされる。単回のけいれん発作後に抗けいれん薬を始めることは妥当であるが、発作のない患者への予防的投与は有害な場合がある。水頭症については、くも膜顆粒からの脳脊髄液の吸収不全による交通性水頭症が 6.6% にみられる。閉塞性水頭症はより稀であるが、脳室内出血により起こる。治療としては脳室吻合術または、持続する場合には、脳室・腹腔シャント術が必要となる。CVT 患者の 40% が頭蓋内圧亢進による症状で発症するとされる。最適な治療についての無作為試験はないが、抗凝固薬や場合によっては血栓溶解薬による静脈血栓の除去、腰椎穿刺による脳内圧の減圧、アセタゾラミドなどが妥当であろう。ステロイド薬は効果がなく、虚血性脳組織に有害である。これらで改善がみられなければ腰椎腹腔シャントを考慮する必要がある。長期の視神経への圧力は失明を招きうるため、視野と乳頭浮腫のモニターが非常に重要であり、稀には視神経開窓術が必要となる。

4) 長期の管理と再発予防 (表 5) : 特定の血栓性素因や疾患では再発リスクが高いと考えられるが、抗凝固薬と再発のリスクについての無作為試験がないため、再発予防策は CVT と DVT に関する観察研究に基づいている。ISCVT 研究では 16 カ月間に CVT の再発 (2.2%) と他の血栓性イベント (4.3%) を合わせて 6.5% にみられ、その 41.5% は抗凝固療法を受けていたが詳細は不明である。血栓性素因 (thrombophilia)には遺伝性と後天性があり、遺伝性の血栓性素因は再発のリスクに従って軽度と重度に層別化される。プロトロンビン G20210A 変異のホモ接合体、第 5 凝固因子 Leiden 変異のホモ接合体、およびプロテイン C、プロテイン S、アンチトロンビン欠乏症、複合血栓性素因異常および抗リン脂質抗体症候群は重度に

属し、頻回にみられる第5凝固因子 Leiden 変異のヘテロ接合体やプロトロンビン G20210A 変異のヘテロ接合体は軽度で分類される。高ホモシステイン血症には遺伝性と後天性があるが、軽度に属する。抗リン脂質抗体症候群は後天性の血栓性素因で臨床検査異常(ループス抗凝固因子、抗カルジオリピン抗体、抗 $\beta$ 2糖蛋白I)と病歴(静脈・動脈性イベントまたは流産)を伴う。臨床検査は最短12週間隔で最低2回施行すべきである。診断が確立すれば無期限の抗凝固療法(INR 2.0~3.0)が推奨される。

5) 晩期合併症の管理: CVT 後の頭痛は約50%の患者にみられ、その多くはCVTと関係のない片頭痛や緊張性頭痛であるが、持続性または重度の頭痛がある患者にはCVTの再発を除外するため適切な検索をすべきである(表1: 推奨クラスI, エビデンス・レベルC)。CVT後の局所または全般性けいれん発作は、早期発症とCVT診断後2週以上を経た晩期発症に分けられる。晩期発作のリスクとしては入院時の出血性病変、早期のけいれん発作、麻痺があげられる。脳実質病変のある患者のけいれん発作後には、一定期間抗けいれん薬を開始することが勧められる。CVTによる視力障害は稀である。乳頭浮腫は一過性の視力障害を起こすが、乳頭浮腫が長期におよぶと視神経萎縮と失明をきたすことがあるため、眼科的精査が必要である。硬膜動静脈瘻は海綿静脈洞、外側静脈洞、矢状静脈洞の血栓症で起こる可能性が高く、DSAが硬膜動静脈瘻の検出に有用である。

## 妊娠中の脳静脈洞血栓症(表6)

妊娠と産褥は凝固亢進状態をもたらす。CVTのリスクが最も高い時期は妊娠第3期から出産後までで、73%が産褥期に起こり、帝王切開もリスクを高める。ワルファリンを含むビタミンK拮抗薬は胎児奇形と胎児・新生児

出血を招くため、妊娠中と産褥初期の抗凝固療法には、大半の症例でLMWHが用いられる。LMWHには催奇性がなく、胎児出血のリスクも高くない。抗凝固療法は妊娠期間中と出産後最低6週間(全体で最低6カ月)継続することが推奨される。静脈性血栓塞栓症の既往がある女性が妊娠した場合には、血栓性イベント(DVT, PE)が高くなる危険があるが、CVTの既往がある女性の妊娠の転帰と合併症を検討した6件の研究では、将来の妊娠中の合併症リスクは低く、88%が正常分娩に至り、その他は妊娠が意図的または自然流産により中止された。CVTの既往をもつ女性の妊娠中のリスクを考慮すると、将来の妊娠期間中と出産後のLMWHによる予防は有益であろう。

## 小児科領域の脳静脈洞血栓症(表7)

新生児はけいれん発作と傾眠で発症し、幼小児はけいれん発作、意識障害、乳頭浮腫を伴う頭痛、頭蓋内圧亢進などで発症する。危険因子については、新生児は出産時に頭蓋にストレスがかかり、抗凝固蛋白が少なく、母親の周産期合併症、子癇前症/子癇も危険因子と考えられる。遺伝性血栓性素因以外に、新生児では頭頸部の感染症、髄膜炎、脱水、先天性心疾患がリスクとなる。年長児・思春期ではループス・エリテマトーデス、ネフローゼ症候群、白血病、リンパ腫、外傷などが危険因子とされる。転帰については、カナダの登録研究において160人の小児の8%に死亡、13%にCVTの再発が認められた。新生児では死亡率は7%であった。治療と管理についての無作為試験が存在しないため、成人のデータから推測する必要があるが、小児と新生児に対するLMWH, UFH, ワルファリンを含む抗凝固療法の有効性が支持されつつある。

(文責: 柳原 武彦)

表1 AHAガイドラインにおける各推奨のクラスとエビデンスレベルの定義

クラス I	検査や治療法の有用性および有効性を示すエビデンスまたは一般的合意がある。
クラス II	検査や治療法の有用性および有効性に関して相反するエビデンスまたは見解の相違が認められる。
クラス IIa	検査や治療法の有用性および有効性を支持するエビデンスまたは見解が多数を占める。
クラス IIb	有用性および有効性を支持するエビデンスや見解は十分ではない。
クラス III	検査や治療法が有用または有効でなく、場合によっては有害となり得ることを示すエビデンスまたは一般的合意がある。
治療の推奨	
エビデンスレベル A	複数の無作為試験またはメタ解析により得られたデータがある。
エビデンスレベル B	1つの無作為試験または複数の非無作為試験より得られたデータがある。
エビデンスレベル C	専門家の合意した見解、症例研究、または標準治療法。
診断の推奨	
エビデンスレベル A	参照基準を用いてマスクされた評価者により施行された複数の前向きコホート研究のデータがある。
エビデンスレベル B	1つのグレードAの研究、または1つ以上の症例対照研究のデータ、あるいは参照基準を使ってマスクされていない評価者により施行された研究のデータがある。
エビデンスレベル C	専門家の合意した見解。



表2 脳静脈洞血栓症の画像診断

推奨	エビデンスの分類とレベル
1. 単純CTまたはMRIは、CVTが疑われる患者の初期評価に有用であるが、陰性所見が得られたからといってCVTの可能性が除外されるわけではない。単純CTまたはMRIが陰性のCVT疑い例や、単純CTまたはMRIでCVTが示唆された患者のCVTの範囲を明らかにするには、静脈造影（CTVまたはMRV）を実施すべきである。	クラスI, エビデンスレベルC
2. 内科的治療を行っても症状が持続ないしは進行するCVT患者や、血栓の伸展を示唆する症状が認められる患者には、CTVまたはMRVにより早期の再検査を実施することが推奨される。	クラスI, エビデンスレベルC
3. CVTの既往があり、CVTを示唆する症状が再発した患者には、CTVまたはMRVによる再検査を実施することが推奨される。	クラスI, エビデンスレベルC
4. グラディエントエコー法または磁化率強調画像と他のMRI法との併用は、CVTの診断精度の向上に有用な可能性がある。	クラスIIa, エビデンスレベルB
5. CTVまたはMRVでは明確な結論が得られなかったものの、臨床的にCVTの疑いが濃厚な患者には、カテーテル脳血管造影が有用な可能性がある。	クラスIIa, エビデンスレベルC
6. 病状の安定した患者には、診断から3～6カ月後にCTVまたはMRVによる再検査を実施し、閉塞した皮質静脈/静脈洞の再開通の評価を行うことが妥当である。	クラスIIa, エビデンスレベルC

CTV：CT静脈造影，CVT：脳静脈洞血栓症，MRV：磁気共鳴静脈造影。

表3 脳静脈洞血栓症急性期の管理と治療

推奨	エビデンスの分類とレベル
1. 急性期CVT患者の管理と治療はStroke Unitで行うのが妥当である。	クラスIIa, エビデンスレベルC
2. 細菌感染が疑われるCVT患者には適切な抗生物質を投与し、適宜CVTと関連した感染源の外科的ドレナージにより、貯留した膿を除去すべきである。	クラスI, エビデンスレベルC
3. ICHの有無にかかわらず、CVT患者には、用量を調整したUFHまたは体重に基づいた十分な抗凝固効果を得られる用量のLMWHによる初期抗凝固療法を行い、その後ビタミンK拮抗薬を投与するのが妥当である。	クラスIIa, エビデンスレベルB
4. 積極的な抗凝固治療を行っても病状が悪化する場合は、血管内治療を検討してもよい。	クラスIIb, エビデンスレベルC

CVT：脳静脈洞血栓症，ICH：脳内出血，LMWH：低分子ヘパリン，Stroke Unit：脳卒中集中治療室，UFH：未分画ヘパリン。

表4 脳静脈洞血栓症の早期合併症の管理と予防

推奨	エビデンスの分類とレベル
1. CVT患者の合併症の治療や予防はStroke Unitで行うのが妥当である。	クラスIIa, エビデンスレベルC
2. 単発のけいれん発作を生じた脳実質病変を伴うCVT患者には、さらなるけいれん発作を予防するために、期間を限定して抗てんかん薬を早期に開始することが推奨される。	クラスI, エビデンスレベルB
3. 単発のけいれん発作を生じた脳実質病変を伴わないCVT患者にも、さらなるけいれん発作を予防するために、期間を限定して抗けいれん薬を早期に開始する適応があるだろう。	クラスIIa, エビデンスレベルC
4. けいれん発作がみられない場合、CVT患者に対する抗てんかん薬の日常的な使用は推奨されない。	クラスIII, エビデンスレベルC
5. 頭蓋内圧亢進を示すCVT患者については、視野欠損の進行の有無を監視することが推奨される。視野欠損の進行が認められる場合は、頭蓋内圧亢進に対する早急な治療が必要である。	クラスI, エビデンスレベルC
6. 頭蓋内圧亢進を示すCVT患者には、アセタゾラミド投与を開始するのが適切である。視野欠損の進行が認められる場合には、他の治療法（腰椎穿刺、視神経減圧術、シャント術）が有効な場合もある。	クラスIIa, エビデンスレベルC
7. 強い圧排効果による神経学的徴候の悪化や頭蓋内出血による難治性の頭蓋内圧亢進が認められる患者には、開頭減圧術を検討してもよい。	クラスIIb, エビデンスレベルC
8. 併存疾患の治療に必要な場合を除き、CT/MRIで脳実質病変が認められても、CVT患者へのステロイド薬投与は推奨されない。	クラスIII, エビデンスレベルB

CVT：脳静脈洞血栓症，Stroke Unit：脳卒中集中治療室。

表5 脳静脈洞血栓症の長期管理および再発予防

推奨	エビデンスの分類とレベル
1. CVT 患者の管理には、プロテイン C、プロテイン S、アンチトロンビン欠損症、抗リン脂質抗体症候群、プロトロンビン G20210A 変異、第 V 因子 Leiden 変異を含む、凝固亢進状態の検査が有益だろう。一般的には、抗凝固療法終了から 2～4 週後に、プロテイン C、プロテイン S、アンチトロンビン欠損症の検査を実施する。急性期の検査やワルファリン投与例への検査はほとんど有用性がない。	クラス IIa, エビデンスレベル B
2. 誘発性（一過性の危険因子を伴う）の CVT 患者には、INR 目標値を 2.0～3.0 として、ビタミン K 拮抗薬の 3～6 カ月継続を考慮してもよい。	クラス IIb, エビデンスレベル C
3. 非誘発性の CVT 患者には、INR 目標値を 2.0～3.0 として、ビタミン K 拮抗薬の 6～12 カ月継続を考慮してもよい。	クラス IIb, エビデンスレベル C
4. CVT 再発例、CVT 後の VTE 症例、または重度の血栓性素因が認められる CVT 初発例（すなわちプロトロンビン G20210A 変異ホモ接合体、第 V 因子 Leiden 変異ホモ接合体、プロテイン C・プロテイン S・アンチトロンビン欠損症、複合的な血栓性素因異常、抗リン脂質抗体症候群）には、INR 目標値を 2.0～3.0 として、無期限の抗凝固療法を検討してもよい。	クラス IIb, エビデンスレベル C
5. 血栓症に詳しい医師に相談し、凝固亢進状態の検査や CVT 患者のケアについて意見を求めてもよい。	クラス IIb, エビデンスレベル C

CVT：脳静脈洞血栓症，INR：国際標準化比，VTE：静脈血栓症。

表6 妊娠中の脳静脈洞血栓症

推奨	エビデンスの分類とレベル
1. CVT のある妊婦には、妊娠期間中、十分な抗凝固効果を得られる量の LMWH を継続すべきであり、出産後は LMWH または INR 目標値を 2.0～3.0 としてビタミン K 拮抗薬を最低限 6 週間継続投与すべきである（総治療期間は最低限 6 カ月とする）。	クラス I, エビデンスレベル C
2. 妊娠中の急性 CVT には、UFH よりも LMWH の投与が妥当である。	クラス IIa, エビデンスレベル C
3. CVT の既往のある女性には、将来的に妊娠は禁忌ではないことを助言することが妥当である。根底にある病因について詳しく調べ、血液専門医や母体・胎児専門医の診察を受けるのが妥当である。	クラス IIa, エビデンスレベル B
4. CVT の既往のある女性が妊娠した場合には、妊娠中および出産後に LMWH を予防的に投与する適応があるだろう。	クラス IIa, エビデンスレベル C

CVT：脳静脈洞血栓症，INR：国際標準化比，LMWH：低分子ヘパリン，UFH：未分画ヘパリン。

表7 小児における脳静脈洞血栓症の管理

推奨	エビデンスの分類とレベル
1. CVT 患児には血液培養と副鼻腔洞 X 線検査を行い、根底に感染症がないかどうかを調べるのが考慮されてもよい。	クラス IIb, エビデンスレベル B
2. CVT 患児には血栓性素因に関する検査を行い、根底にある凝固障害を明らかにするのが有益であろう。障害によっては、その後の再血栓リスクおよび治療上の意思決定に影響を及ぼす可能性がある。	クラス IIb, エビデンスレベル B
3. 急性 CVT を発症した新生児には、LMWH または UFH 投与を考慮してもよい。	クラス IIb, エビデンスレベル B
4. 急性 CVT をきたした新生児には、6 週間～3 カ月にわたって LMWH を継続投与することを考慮してもよい。	クラス IIb, エビデンスレベル C
5. 生後 28 日以降に急性 CVT と診断された小児には、たとえ ICH が認められても、LMWH の充分量の投与が妥当である。	クラス IIa, エビデンスレベル C
6. 生後 28 日以降に急性 CVT と診断された小児には、LMWH または経口ビタミン K 拮抗薬を 3～6 カ月継続投与するのが妥当である。	クラス IIa, エビデンスレベル C
7. 急性 CVT をきたしたすべての小児患者において、初期の抗凝固療法が開始された場合は、治療開始後 1 週間以内に頭部 CT または MRI を実施し、新たな出血を検索するのが妥当である。	クラス IIa, エビデンスレベル C
8. すべての小児患者において、初期の抗凝固療法を行わない場合は、診断後 1 週間以内に静脈造影を含めた脳画像検査を再度実施して、初期血栓の伸長や新規梗塞または出血の有無を監視することが推奨される。	クラス I, エビデンスレベル C
9. CVT 患児に対する支持的処置には、適切な水分補給、てんかん発作のコントロール、頭蓋内圧亢進の治療を含めるべきである。	クラス I, エビデンスレベル C
10. 重度または長期に及ぶ頭蓋内圧亢進により視力障害・視野欠損のおそれがある CVT 患児には、視野および視力検査を定期的実施すべきであり、頭蓋内圧亢進とその合併症の適切な治療を導入すべきである。	クラス I, エビデンスレベル C
11. 急性 CVT の患児はてんかん発作の発現頻度が高いため、意識消失状態にある患児や機械的呼吸を行っている患児には、持続的脳波モニタリングを考慮してもよい。	クラス IIb, エビデンスレベル C
12. 小児患者における血管内治療の有用性および安全性は明らかでないため、有効レベルの抗凝固薬による積極的治療にもかかわらず、神経学的徴候が悪化する患者を慎重に選択し、これらの患者に対してのみ血管内治療を検討してもよい。	クラス IIb, エビデンスレベル C

CVT：脳静脈洞血栓症，ICH：脳内出血，LMWH：低分子ヘパリン，UFH：未分画ヘパリン。

## 脑静脉血栓形成的诊断和处理

一项来自美国心脏协会 / 美国卒中协会针对医疗专业的声明 (摘译)

### Diagnosis and Management of Cerebral Venous Thrombosis A Statement for Healthcare Professionals From the American Heart Association/ American Stroke Association

Gustavo Saposnik, MD, MSc, FAHA, Chair; Fernando Barinagarrementeria, MD, FAHA, FAAN; Robert D. Brown, Jr, MD, MPH, FAHA, FAAN; Cheryl D. Bushnell, MD, MHS, FAHA; Brett Cucchiara, MD, FAHA; Mary Cushman, MD, MSc, FAHA; Gabrielle deVeber, MD; Jose M. Ferro, MD, PhD; Fong Y. Tsai, MD on behalf of the American Heart Association Stroke Council and the Council on Epidemiology and Prevention

**背景:** 此声明旨在提供针对脑静脉窦血栓形成的综述和提供关于其诊断、处理和治疗的推荐意见。面向的读者是负责脑静脉窦血栓形成病人的诊断和处理的医师和其它医疗提供者。

**方法和结果:** 专题组成员是由美国心脏协会卒中理事会科学声明监督委员会任命并代表不同专业领域。专题组以 1966 年以来发表的报告为重点, 对相关文献做了回顾, 并使用美国心脏协会证据水平分级方法对证据进行评价和制定建议。声明经专题组批准之后, 再经同行评议并通过美国心脏协会科学顾问和协调委员会的批准。

**结论:** 对脑静脉血栓形成的诊断、处理及复发的预防提供了基于证据的建议。提供了关于妊娠期和儿童人群中脑静脉血栓形成的评价和处理的建议, 也总结了关于临床并发症(抽搐发作、脑积水、颅内压增高以及神经系统症状和体征恶化)处理的思考。描述了脑静脉窦血栓形成病人的诊断和处理流程。

**关键词:** 美国心脏协会科学声明; 静脉血栓形成; 硬膜窦血栓形成, 颅内; 脑梗死, 静脉性; 卒中; 疾病处理; 预后; 结局评估; 抗凝剂; 妊娠; 儿童

(*Stroke*. 2011;42:1158-1192. 北京天坛医院神经内科 曹亦宾 摘译 王拥军 校)

硬脑膜窦和(或)脑静脉血栓形成(CVT)是一种不常见的卒中类型, 通常好发于年轻人<sup>[1]</sup>。危险因素具有多样性, 缺乏统一的治疗方法, 临床诊断和处理可能困难。CVT大约占所有卒中的0.5%-1%<sup>[2]</sup>。诱发因素包括先存疾病(如易栓症、炎症性肠道疾病)、一过性疾患(诸如妊娠、脱水、感染)、某些药物(诸如口服避孕药、毒品滥用)及不可预见的事件(诸如头部外伤)<sup>[3,4]</sup>。

CVT的病因和临床表现形式具有多样性, 不仅是神经内科和神经外科医生而且也是急诊科、普通

内科、肿瘤科、血液科、妇产科、儿科以及家庭医生经常遇到的临床问题。本科学声明旨在回顾 CVT 的相关文献并提供诊断和处理建议。

#### CVT的流行病学和危险因素

CVT是一种少见且经常被误诊的卒中类型, 年发病率大约为 5/100 万, 占所有卒中的 0.5%-1%<sup>[1]</sup>。CVT 更常见于青年个体。脑静脉和硬脑膜窦血栓形成国际研究 (ISCVT) 报告的 624 例中有 487 例 (78%) 病人的年龄小于 50 岁<sup>[1,6]</sup>。还没有人群研究报告过

Author order is alphabetical after the writing group chair. All authors have contributed equally to the present work.

The American Heart Association makes every effort to avoid any actual or potential conflicts of interest that may arise as a result of an outside relationship or a personal, professional, or business interest of a member of the writing panel. Specifically, all members of the writing group are required to complete and submit a Disclosure Questionnaire showing all such relationships that might be perceived as real or potential conflicts of interest.

This statement was approved by the American Heart Association Science Advisory and Coordinating Committee on October 26, 2010. A copy of the statement is available at <http://www.americanheart.org/presenter.jhtml?identifier=3003999> by selecting either the "topic list" link or the "chronological list" link (No. KB-0186). To purchase additional reprints, call 843-216-2533 or e-mail [kelle.ramsay@wolterskluwer.com](mailto:kelle.ramsay@wolterskluwer.com).

The American Heart Association requests that this document be cited as follows: Saposnik G, Barinagarrementeria F, Brown RD Jr, Bushnell CD, Cucchiara B, Cushman M, deVeber G, Ferro JM, Tsai FY, on behalf of the American Heart Association Stroke Council and the Council on Epidemiology and Prevention. Diagnosis and management of cerebral venous thrombosis: a statement for healthcare professionals from the American Heart Association/American Stroke Association. *Stroke*. 2011;42:1158-1192.

Expert peer review of AHA Scientific Statements is conducted at the AHA National Center. For more on AHA statements and guidelines development, visit <http://www.americanheart.org/presenter.jhtml?identifier=3023366>.

Permissions: Multiple copies, modification, alteration, enhancement, and/or distribution of this document are not permitted without the express permission of the American Heart Association. Instructions for obtaining permission are located at <http://www.americanheart.org/presenter.jhtml?identifier=4431>. A link to the "Permission Request Form" appears on the right side of the page.

© 2011 American Heart Association, Inc.

CVT 的患病率。

#### 病因和发病机制: CVT的潜在危险因素

CVT 的诱因是多方面的。危险因素通常被归类为获得性危险(诸如手术、创伤、妊娠、围产期、抗磷脂抗体综合征、癌症、外源性激素)和遗传性危险(遗传性易栓症)。

表 3 总结了促凝因素与 CVT 之间因果关系<sup>[10,11]</sup>的证据<sup>[12-55]</sup>。总结的证据涉及联系强度和一致性、生物学可信度及时间性。其中,最符合这些标准的是抗凝血酶 III 缺乏、蛋白 C 和蛋白 S 缺乏症、凝血因子 V(factor V)Leiden 阳性、使用口服避孕药及高同型半胱氨酸血症。

#### 血栓前状态

血栓前状态是研究最广泛的 CVT 危险因素之一。ISCVT 研究发现 34% 的 CVT 病人有遗传性或获得性血栓前状态<sup>[10]</sup>。

#### 抗凝血酶III、蛋白C和蛋白S缺乏症

两项研究已经对天然抗凝蛋白缺乏症(抗凝血酶 III、蛋白 C 和蛋白 S)作为 CVT 危险因素的作用进行了分析。一项研究对 121 例首次患 CVT 的病人和 242 例健康对照者进行了比较<sup>[36]</sup>。另一项研究对 51 例 CVT 病人和 120 例健康对照者进行了比较<sup>[12]</sup>。仅 1 例病人(2%)有抗凝血酶 III 缺乏。将两项研究合并之后,蛋白 C 缺乏症患者 CVT 危险的合并比值比(odds ratio, OR)是 11.1(95% 可信区间 [CI] 1.87-66.05;  $P=0.009$ ),而蛋白 S 缺乏症是 12.5(95% CI 1.45-107.29;  $P=0.03$ )。

#### 抗磷脂和抗心磷脂抗体

一项研究发现 CVT 病人中抗磷脂抗体的发生率(9/121)高于对照组(0/242)<sup>[36]</sup>。另一项研究中,与正常人对照组的 3.2% 相比,31 例 CVT 病人中 22.6% 被检测出抗心磷脂抗体<sup>[12]</sup>。ISCVT 研究观察到的结果与之相似(5.9%)<sup>[10]</sup>。

#### 凝血因子V Leiden基因突变和活化蛋白C抵抗

活化蛋白 C 抵抗主要是由凝血因子 V Leiden 基因突变所致,而凝血因子 V Leiden 基因突变是一种常见的遗传性易栓性疾病。

#### 凝血酶原G20210A基因突变

凝血酶原 G20210A 基因突变大约见于 2% 的白种人,它能导致凝血酶原水平的轻度增高<sup>[55,56]</sup>。一项对 9 项研究共 360 例 CVT 病人和 2688 例对照受

试者的 meta 分析报告<sup>[38]</sup>,此种基因突变的 CVT 混合 OR 值为 9.27(95% CI 5.85-14.67)<sup>[28]</sup>,比它与总的静脉血栓栓塞(VTE)的相关性要强。

#### 高同型半胱氨酸血症

高同型半胱氨酸血症是深静脉血栓形成(DVT)和卒中的一个危险因素,但对其与 CVT 危险性增加的相关性还不清楚。

#### 妊娠和产褥期

妊娠和产褥期是一过性血栓前状态的常见原因<sup>[57]</sup>。大约 2% 的妊娠相关性卒中可归咎于 CVT<sup>[31]</sup>。据估计,产褥期 CVT 的发生率为 12/10 万次分娩,仅略低于产褥期动脉性卒中<sup>[58]</sup>。

大多数妊娠相关性 CVT 发生在妊娠晚期或产褥期<sup>[32]</sup>。妊娠可诱发凝血系统发生若干促凝改变,这些改变至少持续至产褥期的早期。分娩后由于血容量丢失和创伤可加重高凝状态。在产褥期,其它危险因素还有感染和器械辅助分娩或剖腹产等。

#### 口服避孕药

应用口服避孕药与 CVT 危险增加有关,大多数患 CVT 的年轻非妊娠妇女是口服避孕药者,而在那些有某种遗传性易栓因素的妇女中口服避孕药者患 CVT 的危险更大。

#### 癌症

据推测, CVT 在癌症特别是血液系统恶性肿瘤病人中或许更常见,但还未见到有对照组的研究。癌症与 CVT 之间联系的潜在机制包括肿瘤直接压迫、肿瘤侵犯脑静脉窦<sup>[39-41]</sup>或癌症伴随的高凝状态<sup>[60]</sup>。用于癌症治疗的化疗药物和激素也可能起到一定作用。

#### 其它少见病因

新的神经影像技术近年来提高了发现 CVT 的能力并且也有助于识别出其它潜在的病因,其中包括感染,主要是位于脑膜附近部位(耳、副鼻窦、口腔、面部及颈部)的感染。感染所致的 CVT 在成年人中并不多见,但在儿童中却很常见。

一些个案病例报道和小规模病例系列研究已将其它疾患与 CVT 联系在一起,包括阵发性睡眠性血红蛋白尿、缺铁性贫血、血小板减少症、肝素诱导性血小板减少症、血栓性血小板减少性紫癜、肾病综合征、炎症性肠道疾病、系统性红斑狼疮、白塞氏病、硬膜外血肿、自发性低颅压以及腰穿。

## CVT的临床诊断

### 主要临床表现

CVT的诊断通常基于临床怀疑和影像检查证实。根据神经系统功能障碍的机制,通常将CVT的临床表现分为两大类:一类与静脉引流受阻所致的颅内压增高有关,另一类与静脉性缺血/梗死或出血所致的局灶性脑损伤有关。头痛是CVT最常见的症状,见于近90%的病人<sup>[10]</sup>。CVT所致头痛常为弥漫性且常有数天至数周的进行性加重。少数病人可表现为霹雳样头痛或偏头痛型头痛。没有局灶性神经系统表现或视乳头水肿的孤立性头痛可见于高达25%的CVT患者<sup>[65]</sup>。对于有头痛和视乳头水肿或复视(外展神经麻痹所致)的病人,即使没有其它提示特发性高颅内压的神经系统局灶性体征,CVT也是一个重要的诊断考虑。当因静脉性缺血或出血而发生局灶性脑损害时,经常出现与受累脑组织区域相符的神经系统体征和症状;最常见为偏瘫和失语,但其它皮层体征或感觉症状也可发生。精神异常伴局灶性神经系统体征的情况也有报道<sup>[66]</sup>。

临床表现还与血栓形成的部位有关。上矢状窦受累最常见,可导致头痛、颅内压增高和视乳头水肿<sup>[67]</sup>,也可出现运动缺失症状,有时伴有抽搐。在横窦静脉血栓形成,由于皮层受累,有时可以见到偏盲、对侧肢体无力及失语,可以发现与某一原发疾病有关的症状(中耳感染)<sup>[69]</sup>。深部脑静脉系统(大脑内静脉、大脑大静脉及直窦)的血栓形成,可导致丘脑或基底节梗死。皮层静脉血栓形成少见<sup>[76]</sup>。

一些临床特征有助于区分CVT和其它发病机制的脑血管病。首先,局灶性或全身性抽搐发作是常见的,大约发生于40%的病人。其次,常有双侧大脑半球受累,这一特征在深部静脉引流系统受累的病例中特别明显,当发生双侧丘脑受累时,可导致意识水平的改变而没有局灶性神经系统症状和体征。由于上矢状窦血栓形成和双侧半球受损,也可出现双侧运动受累体征,包括截瘫。最后,CVT病人经常有缓慢进展的症状。CVT诊断常有延迟,而且令人印象深刻。

### 其它临床和实验室检查

#### 常规血液检查

对怀疑CVT的患者有必要做全血细胞计数、生化、血沉以及凝血酶原时间和部分活化的凝血活酶时间测定。这些检查可发现一些异常,提示潜在高凝状态、感染过程、或炎症状态,所有这些情况都可促使CVT的发生发展。

### 建议

1. 对怀疑CVT的病人,应该做由全血细胞计数、

生化、凝血酶原时间及活化的部分凝血活酶时间组成的常规血液检查(I级推荐;C级证据)。

2. 推荐在首次临床评估时筛查可诱发CVT的潜在易栓疾患(诸如应用避孕药、潜在炎症性疾病、感染过程)(对检测血栓形成倾向的特殊建议参见本文件的长期处理部分)(I级推荐;C级证据)。

### 腰椎穿刺

除非临床怀疑脑膜炎,否则脑脊液(CSF)检查对有局灶性神经系统功能异常和放射学上已确定CVT诊断的病人通常没有帮助。对急性头痛就诊的病人,腰穿初压增高可能是诊断CVT的一个线索。细胞数增高(大约见于50%的病人)和蛋白增高(约见于35%)是常见的,但没有细胞数和蛋白增加并不妨碍考虑CVT的诊断<sup>[10]</sup>。

### D-二聚体

D-二聚体对CVT的特异性差,许多原因可导致D-二聚体增高。研究表明D-二聚体测定有助于临床上排除CVT<sup>[77-81]</sup>。

### 建议

1. 一种敏感的免疫测定方法或快速酶联免疫吸附法(ELISA)测定的正常D-二聚体水平可以被考虑有助于识别患CVT概率低的病人(III级推荐;B级证据)。如果临床上高度怀疑CVT,则D-二聚体水平正常不应该妨碍进一步的评估。

### CVT诊断中的常见遗憾

有几种临床情景经常发生CVT的误诊或延迟诊断。

### 脑出血

大约30%-40%的CVT病人表现为脑出血(ICH)<sup>[14,84]</sup>。鉴于这类病例中脑出血的发病机制有别于其它ICH的原因,识别出这些病人至关重要,对治疗有重要意义。提示ICH的病因为CVT的特征包括先驱性头痛(在其它原因ICH中很不寻常)、双侧脑实质异常以及有高凝状态的临床证据。单纯蛛网膜下腔出血的发生也可能是CVT所致,尽管这种情况罕见(在ISCVT研究中占0.8%)。出血部位对评估CVT的可能性也是一个重要考虑内容。

### 建议

1. 对原因不甚明确的脑叶ICH或跨经典动脉分布界限的脑梗死病人,应该做脑静脉系统的

### 成像 (I 类推荐; C 级证据)。

#### 孤立性头痛/特发性颅内压增高

将 CVT 与特发性颅内压增高区分开有重要的转归和治疗意义, 建议对所有临床上认为特发性颅内压增高的病人进行脑静脉系统的成像<sup>[67,85]</sup>。对于孤立性头痛的病人, 识别 CVT 的合理策略还不十分清楚。头痛是一个相当常见的症状, 而且绝大多数单纯头痛的病人都不会有 CVT。常规影像检查的成本-效益比和获益十分不确定。可能提示诊断并因此促使影像评估的因素包括新发的经保守治疗仍在数天至数周之内持续进展的不典型头痛以及霹雳样头痛<sup>[64]</sup>。对有某种高凝状态的头痛病人, 应高度警惕 CVT。

#### 建议

1. 对临床上认为特发性颅内压增高的病人, 推荐做脑静脉系统成像以排除 CVT (I 类推荐; C 级证据)。
2. 对有不典型特征的头痛病人, 为排除 CVT 而做脑静脉系统成像是合理的 (IIa 推荐; C 级证据)。

#### 孤立性精神状态改变

偶尔, CVT 病人可表现为嗜睡或意识浑浊而没有明显的局灶性神经系统功能异常<sup>[86-88]</sup>。这类临床表现常见于老年人和有深静脉系统血栓形成者<sup>[89,90]</sup>。尽管此种临床表现有许多发病机制, 但是一个重要原因是深静脉系统受累所致的双侧丘脑病变。CT 扫描, 尤其在病程早期做时, 可无特殊改变; MRI 在这类病例通常会显示出异常。

### CVT 诊断性影像学检查

在过去 20 年间, 诊断性影像学检查在 CVT 的诊断和处理方面所起的作用越来越大<sup>[2,3,55,91-97]</sup>。CVT 的诊断性成像可被分为两类: 无创检查和有创检查。目的是明确与本病有关的血管和脑实质改变。部分病例仅能靠脑血管数字减影做出诊断<sup>[72,91,98-100]</sup>。

#### 无创诊断检查方法: CT、MRI 及超声

##### CT

平扫头部 CT 是诊断 CVT 的首选检查, 可以发现一些提示 CVT 的征象。静脉窦解剖变异使得 CT 对 CVT 的诊断不具敏感性, 大约仅有 30% 的 CVT 病人在 CT 上有异常所见<sup>[1,28,70,94,95,98]</sup>。急性期 CVT 在平扫 CT 上的主要征象是某一皮层静脉或硬脑膜窦呈高密度改变。然而, 大约仅有 1/3 的 CVT 被发现有高密度硬脑膜窦的直接征象<sup>[70,94,96]</sup>。上矢状窦后部血栓可以看似一个高密度三角, 即高密度或实

心的  $\delta$ (delta) 征。平扫 CT 也可显示缺血性梗死, 有时伴有出血成分。横跨常见动脉分界的 (特别是有出血成分的) 或紧邻某一静脉窦的缺血性梗死提示 CVT<sup>[93]</sup>。蛛网膜下腔出血和 ICH 并不常见<sup>[99]</sup>。蛛网膜下腔出血仅见于 0.5%-0.8% 的 CVT 病人<sup>[10,14,99]</sup>, 而且一旦出现, 其部位常在大脑凸面, 恰与在动脉瘤破裂病人中经常观察到的 Willis 环区域相反。

强化 CT 可以显示静脉窦的硬膜强化伴静脉或静脉窦内的充盈缺损, 呈典型的“空  $\Delta$ ”征 (empty delta sign)<sup>[93]</sup>。这种征象在症状起病后数日内可能不会出现但可持续数周。

由于 CVT 的症状可能被疏忽或延迟就诊, 使得 CVT 可能只有在亚急性期或慢性期才被发现。与邻近脑组织的密度相比, 血栓可以呈等密度、低密度或混杂密度。这种情况下, 强化 CT 或 CT 静脉造影术 (CTV) 可能有助于影像学诊断<sup>[70-74,94,97,100-105]</sup>。

#### 磁共振成像

通常, MRI 对 CVT 的显示在脑静脉血栓形成的每个阶段都比 CT 敏感<sup>[1,70,96,97,101,106,107]</sup>。通过在 MRI 上发现某一静脉窦内有血栓可做出 CVT 的诊断<sup>[105,108-113]</sup>。孤立性皮层静脉血栓被发现的几率比静脉窦血栓要小得多。静脉血栓的磁共振信号强度随成像检查时间距血栓形成的发生时间长短而变化<sup>[6,65,94,101-107]</sup>。急性血栓可以是低信号。在第 1 周, 由于脱氧血红蛋白含量的增加, 静脉血栓通常在 T1 加权像上呈与脑组织相等的等信号而在 T2 加权像上呈低信号。到第 2 周, 血栓含有氧化血红蛋白, 导致其在 T1 和 T2 加权像上均呈高信号<sup>[2,10,42,70,71,73,74,91,98-100,105,106,108,113-128]</sup>。随着血栓的演变, 静脉窦内出现脱氧血红蛋白和氧化血红蛋白的顺磁性代谢产物。此时硬膜窦或静脉内血栓在梯度回波和磁敏感加权磁共振成像上呈低信号<sup>[70,119,129]</sup>。

CVT 在平扫 MRI 上的主要早期征象是硬膜窦内流空影消失和信号强度改变。这一征象是 CT 空  $\Delta$  (delta) 征的等位征。急性静脉血栓可以呈酷似正常流空影的等信号, 为确立诊断可能需要做强化 MRI 和 CTV 或 MR 静脉造影 (MRV)。

MRI 的次要征象与 CT 显示的类型可能相似, 包括脑肿胀、水肿和 (或) 出血<sup>[91,130-134]</sup>。CVT 脑实质病变在 MRI 上比在 CT 上更直观更清晰。点片状或融合成片状出血提示出血性静脉梗死。在一定程度上, 与特定静脉窦有关的病变呈区域性分布。额叶、顶叶和枕叶的脑实质改变通常对应上矢状窦血栓形成。颞叶脑实质改变对应侧 (横) 窦和乙状窦血栓形成。深部脑实质异常, 包括丘脑出血、水肿或脑室内出血, 与 Galen 静脉或直窦血栓形成对应。

### CT静脉造影

CTV 为显示 CVT 提供了一种快速和可靠的检查方法, 对亚急性期或慢性期 CTV 的诊断更有帮助。在诊断 CVT 方面, CTV 至少可与 MRV 媲美 [94,97,100,101,103,106]。

### 磁共振静脉造影

最常用的 MRV 技术是时间飞跃 (TOF)MRV 和造影剂增强磁共振。二维 TOF 比三维 TOF 对缓慢血流的敏感性好。静脉窦发育不良在梯度回波或敏感加权成像上不会有窦内异常低信号。

对内科药物治疗下仍有持续的或进展性症状的病人, 重复影像学检查 (包括 CTV 或 MRV) 可有助于识别新的缺血性病变、ICH、水肿、血栓扩展及其它脑实质病变的发生发展 [97,110,111,120,128,136-138,140,141]。

### 深部CVT

深部静脉系统在 CT 和 MRI 上容易被显示且很少受到伪差的影响。

### 有创的诊断性血管造影检查

#### 脑血管造影和直接脑静脉造影

有创的脑血管造影在有 MRV 和 CTV 的情况下很少被用来确立 CVT 的诊断 [109,125,133], 只有在 MRV 或 CTV 的结果没有定论或考虑行血管内治疗的情况下才做。

### 脑血管造影

血管造影的结果包括因闭塞所致的静脉窦不显影、静脉淤滞伴扩张的皮层、头皮或面部静脉、侧支引流微小静脉的扩张以及静脉血流逆转。脑血管造影的静脉期显示在形成血栓的脑静脉 / 窦内有充盈缺损。脑静脉或硬膜窦发育不良或闭锁可以导致 MRV 或 CTV 的结果没有定论, 但是可被脑血管造影的静脉期澄清。急性期硬膜窦或皮层静脉血栓通常导致脑静脉期的延迟, 而且脑血管造影可以显示脑静脉结构显影的延迟或缓慢。正常情况下, 早期静脉在造影剂被注射到颈动脉之后的 4-5 秒开始显影, 而整个脑静脉系统在 7-8 秒显影 [74,91,124,152]。如果脑静脉或硬膜窦在脑血管造影的正常序列中不能被显示, 则怀疑急性血栓形成的可能性。

### 直接脑静脉造影

直接脑静脉血管造影是经颈内静脉途径利用微导管直接将造影剂注射到某一硬膜窦或脑静脉来进行 [74,91]。直接脑静脉造影通常是在血管内治疗操作过程中进行。在直接脑静脉造影上, 管腔内血栓可被显示为管腔内充盈缺损或完全不显影。直接脑静脉造影过程中还可做静脉压力测定以识别静脉压增

高。正常静脉窦压力 <10 mm H<sub>2</sub>O。

### 其它诊断性检查方法

经凶门超声可被用于评估儿童病人, 包括前后凶门未闭合的新生儿或婴幼儿。超声和经颅多普勒可能有助于支持 CVT 的诊断和连续监测血栓和脑实质的改变 [152,154,155]。

### 灌注成像方法

应用正电子发射断层扫描的经验性证据表明, 上矢状窦结扎同时伴有静脉性梗死后有脑血流量的降低 [156]。在年轻成年上矢状窦血栓形成病人也观察到局部脑血容量的增加 [157]。与在缺血性动脉性卒中病人观察到的类型 (平均通过时间延长和脑血容量降低) 相反, 平均通过时间延长和脑血容量增加提示为静脉淤滞 [111,124]。

CVT放射学诊断方面的潜在缺陷: 解剖变异、血栓信号多变性以及影像伪差

经 CT 或 MRI 发现血管腔内血栓是 CVT 确诊的关键。然而, 正常脑静脉解剖变异 (包括静脉窦闭锁 / 发育不良、不对称静脉引流以及蛛网膜颗粒或窦间分隔所致的正常静脉窦充盈缺损) 可以酷似静脉窦血栓形成, 有时靠无创的成像检查除外 CVT 是不可能的 [2,71,72,95,97,106,108,109,125,142-150,158]。直接脑静脉造影因逆流注射造影剂而可能难以解释, 而静脉压又因静脉系统内的相对分隔效应而可能不准确 [70]。

### 建议

1. 尽管平扫 CT 或 MRI 有助于疑似 CVT 病人的最初评估, 但是平扫 CT 或 MRI 结果阴性并不能排除 CVT。对疑似 CVT 的病人, 如果平扫 CT 或 MRI 阴性或在平扫 CT 或 MRI 提示 CVT 情况下为确定 CVT 的范围, 应做静脉造影检查 (CTV 或 MRV) (I 类推荐; C 级证据)。
2. 对内科治疗下仍有持续的或演变的症状或有提示血栓扩大的症状的 CVT 病人, 建议早期随访 CTV 或 MRV (I 类推荐; C 级证据)。
3. 对表现为提示 CVT 复发病状的既往有 CVT 的病人, 建议复查 CTV 或 MRV (I 类推荐; C 级证据)。
4. 梯度回波 T2 磁敏感加权成像联合磁共振可能有助于提高 CVT 诊断的准确性 (IIa 类推荐; B 级证据)。
5. 对 CTV 或 MRV 没有定论但临床上仍高度怀疑 CVT 的病人, 导管脑血管造影可能有帮助 (IIa 类推荐; C 级证据)。

## 6. 对病情稳定的病人，为了评价闭塞皮层静脉/静脉窦的再通情况，在诊断后 3-6 个月时随访 CTV 或 MRV 是合理的 (IIa 类推荐; C 级证据)。

### CVT 急性期处理和治疗

本文提供了 CVT 病人诊断和处理的简要程序。

#### 环境

组织化医疗是降低急性卒中后残疾率和死亡率的最有效干预措施之一<sup>[166,167]</sup>。CVT 是一种不常见但又可能危及生命的卒中病因。基于卒中单元的总疗效，为了优化治疗和减少并发症，在卒中单元内进行 CVT 的初始处理是合理的。

#### 初始抗凝治疗

CVT 抗凝疗法有若干理由：预防血栓增长、促进血管再通以及预防深静脉血栓 (DVT) 或肺栓塞 (PE)。因为在 CVT 诊断时常存在脑梗死伴出血转化或 ICH，这种情况也可使治疗复杂化，因此对抗凝治疗一直有争议。

现有两项随机对照试验，在经造影剂强化成像检查确诊的 CVT 病人中对抗凝治疗和安慰剂或开放对照进行了比较。合起来看，这两项试验仅纳入 79 例病人。一项 20 例病人的试验对采用剂量调节的以活化的部分凝血活酶时间达治疗前数值的两倍的静脉内普通肝素 (UFH) 和安慰剂进行了评价<sup>[171]</sup>。此研究使用肝素的方法为 3000 单位团注后持续静脉输注。主要结局是 3 个月时评估头痛、局灶体征、抽搐发作和意识水平的 CVT 严重程度量表。次要结局是 ICH。此试验因有治疗获益而在纳入预期 60 例病人中的 20 例时被提前终止。在 3 个月时，肝素组 10 例病人中，8 例完全恢复，2 例有轻度神经功能缺失。安慰剂组 10 例病人中，3 个月时 1 例完全恢复，6 例有轻度神经功能缺失，3 例死亡。发生 ICH 者见于 2 例安慰剂治疗的病人而未见于肝素治疗的病人。安慰剂组中 1 例病人有未经证实的肺栓塞。

另一项 59 例病人的试验对剂量基于体重 (180 抗 Xa 因子单位 / 天 / 公斤体重，分两次剂量) 的皮下注射低分子肝素 (nadroparin) 和安慰剂进行了比较，疗程为 3 周，随后被随机化到低分子肝素组的病人接受 3 个月的口服抗凝治疗 (没有安慰剂对照)<sup>[172]</sup>。此研究在前 3 周为盲法而随后为开放标签。主要结局是日常生活活动量表、牛津卒中残疾量表及死亡。次要终点是症状性 ICH 和其它严重出血。在 3 个月时，与给予安慰剂者的 21% 相比，13% 的低分子肝素组病人的预后不良 (有利于低分子肝素的治疗差异 -7% ; 95% CI -26-12%)。两组中都没有症状性

ICH (低分子肝素组有 1 例非致命性出血，安慰剂组有 1 例致命的未被证实的肺栓塞)。6 例积极治疗的病人 (12%) 和 8 例对照病人 (28%) 3 个月时完全恢复。

对这 2 项试验的 Meta 分析<sup>[161]</sup>显示，抗凝治疗的死亡或生活不能自理的相对危险度 (relative risk 0.46, 95% CI 0.16-1.31) 没有统计学显著性，对抗凝治疗有利的危险差异 -13% (95% CI -30%-3%)。死亡的相对危险度是 0.33 (95% CI 0.08-1.21)，危险差异是 -13% (95% CI -27%-1%)。

在就诊时 CVT 合并脑出血的特殊情况下，即使不用抗凝治疗，出血也与不良预后有关。研究提示 CVT 抗凝治疗后脑出血的发生率低<sup>[171,175]</sup>。在病人有抗凝治疗主要禁忌证 (如近期严重出血) 的特殊情况下，临床医生必须依据临床情况权衡抗凝治疗的风险和益处。在这种情况下，就像对待一般静脉血栓一样，请一位抗凝治疗方面的专家会诊可能是适当的，如果有可能，可以考虑低剂量强度抗凝治疗。

#### 来自观察性研究的资料

现有许多观察性研究，既有前瞻性的，也有回顾性的，但大多数来自单中心<sup>[10,136,175-178]</sup>。因为大多数研究中绝大多数病人在诊断时是用静脉 UFH 或低分子肝素 (LMWH) 治疗的，最终应用维生素 K 拮抗剂，因此，并非所有的研究都专门报告抗凝治疗的结局。死亡率低，通常 < 10%，常死于基础病 (如，癌症) 而不是 CVT，而且死于 ICH 罕见。绝大多数病人神经系统功能完全恢复，少数变成残疾。

目前为止最大规模研究为 ISCVT，纳入来自 21 个国家 89 个中心的 624 例病人。几乎所有病人初始治疗为抗凝，16 个月死亡率 8.3%，79% 完全恢复 (改良 Rankin 评分 [mRS] 评分 0-1)，10.4% 轻 - 中度残疾 (mRS 评分 2-3)，2.2% 仍有重度残疾 (mRS 评分 4-5)<sup>[10]</sup>。几乎没有研究有足够的未接受抗凝治疗的病人例数来合理推断抗凝与预后之间的关系。来自观察性研究的资料提示 CVT 抗凝后 ICH 的危险范围是 0 到 5.4%<sup>[136,171,181,183]</sup>。

总之，来自有限的关于抗凝治疗的预后和出血并发症的随机对照试验的资料和观察性资料支持抗凝在 CVT 治疗中起到一定作用，无论是否存在治疗前 ICH。写作组一致支持在 CVT 病人处理中采用抗凝治疗。如果给予抗凝治疗，没有支持在 CVT 病人中采用以调整的剂量 UFH 的应用或 LMWH 在预后方面的差异的资料。

#### 其它治疗

##### 纤维蛋白溶解疗法

尽管 CVT 病人接受抗凝治疗可以恢复，但是在抗



凝治疗下仍有 9%-13% 的病人预后不良。单纯抗凝治疗或许不能使一个大的或广泛的血栓溶解,而临床情况即使在肝素治疗期间也会恶化<sup>[2,6,10,74,84,95,164,170,172,185-191]</sup>。不完全再通或持续性血栓形成可以解释这一现象。单纯抗凝治疗下 CVT 部分或完全再通率为 47%-100%<sup>[110,178,192-194]</sup>。

不幸的是,大多数报告 3-6 个月时部分或完全再通的研究为小样本研究。将共包括 114 例病人的 4 项研究合并后,发现 94 例 (82.5%) 在 3-6 个月时有部分或完全再通<sup>[110,178,192,193]</sup>。接受溶栓治疗的病人再通率可能更高<sup>[14]</sup>。通常,如果在抗凝治疗下仍有临床恶化或如果某一病人在其他处理方法下仍有进行性颅内压增高,则采用溶栓治疗。

血管内介入治疗还没有得到来自与抗凝治疗相比较的或相互之间相比较的随机对照试验的支持。大多数证据基于小规模病例系列或经验性病例报告。

### 直接导管溶栓

在直接导管溶栓时,血栓经导丝的机械性操作之后可增加可能受到溶栓药物作用的血凝块的数量,可减少溶栓药物的用量<sup>[61,113,131,150,170,188,192,195-205]</sup>。

美国的一项回顾性多中心 CVT 研究中,182 例病人中的 27 例 (15%) 接受了血管内溶栓治疗。10 例病人正在接受同期抗凝治疗。26 例 (96%) 获得血管再通,4 例发生颅内出血,1 例 (4%) 病人死亡。

一项对包括 169 例局部溶栓治疗的 CVT 病人的系统性回顾显示严重 CVT 病人可能从治疗中获益,提示局部溶栓治疗能降低危重 CVT 病人的病死率。溶栓后 17% 的病人发生 ICH,与 5% 的病人病情恶化有关<sup>[206]</sup>。

### 机械性取栓/溶栓

#### 球囊辅助的取栓和溶栓

尽管使用全身性溶栓或对血凝块行机械性破碎和直接注射溶栓药物,但是静脉窦血栓可能仍持续存在。因为球囊充盈后可以减少溶栓药物的流失而潜在地减少所需要的溶栓药物剂量、降低出血的发生率<sup>[74,207,208]</sup>以及缩短操作时间,所以球囊辅助的溶栓或许更有效。在溶栓前可以用球囊做部分性血栓去除术<sup>[112,209]</sup>。

#### 导管血栓去除术

对局部应用溶栓药后仍持续存在的广泛血栓病人,可以考虑采用流变 (rheolytic) 导管血栓去除术。AngioJet(MEDRAD, Inc, Warrendale, PA) 就是一种这样的装置,它采用通过高速生理盐水喷头的文丘里效应 (Venturi effect) 而发生在导管头端的流体动

力学溶栓作用。

Merci 取栓装置 (Concentric Medical, Mountain View, CA) 也已经被用于去除脑静脉系统的血栓。此技术也需要将导管直接送到静脉窦。将小螺旋形装置送出导管头端并被推送进血栓内,然后缓慢地与附着的血栓一起被拉回到导管内。为了避免损伤静脉窦壁或窦内小梁,可以先用此装置行部分再通,随后再进行溶栓<sup>[195]</sup>。现有证据目前尚处在经验阶段。

Penumbra 系统 (Penumbra, Inc, Alameda, CA) 是新一代神经系统血栓去除装置,能起到去除和抽吸急性血凝块的作用。它采用一个内有能破碎血凝块和有助于抽吸的一个基于导丝的分离器的能抽吸血栓的再灌注导管。关于其治疗效果目前仅有经验性的证据<sup>[212]</sup>。

### 手术方面的考虑

由于静脉血栓形成血管内治疗方法的进展,外科手术所起的作用已经越来越局限。需要外科手术血栓切除术者不常见,但如果在最佳内科治疗下严重的神经系统或视力恶化发生可以被考虑<sup>[213,214]</sup>。如果大的静脉性梗死导致明显的颅内压增高时,则需开颅减压术作为挽救生命的措施。同样,大的血肿如果伴有进行性或严重的神经系统功能缺失可能需要被考虑做手术清除术。

### 总结

这些直接窦内溶栓技术和机械性治疗方法的运用仅受到个案报告和小规模病例系列的支持。如果在应用抗凝治疗的情况下仍发生临床恶化,或病人出现导致常规治疗方法抵抗的颅内压增高的来自静脉梗死或 CIH 的占位效应,那么可以考虑这些介入治疗技术。

### 阿司匹林

没有直接评价阿司匹林在 CVT 处理中作用的对照试验。

### 激素

激素通过减轻血管源性水肿而可能在 CVT 中起到一定作用,但激素可以增加高凝状态。在 ISCVT 的 624 例病人中一项匹配的病例-对照研究中<sup>[216]</sup>,将 150 例由经治医生决定采用激素治疗的病人与 150 例未采用激素的病人进行比较,并与基于 CVT 结局不良的预后因素治疗的病人匹配。采用激素治疗的病人与对照病人的特征相似,除了更容易有血管炎。在 6 个月,治疗有死亡或不能独立的危险较大的趋势 (OR 1.7, 95% CI 0.9-3.3),而在排除血管炎、恶

性病、炎性疾病及感染后，这一趋势没有差别。在 CT/MRI 上有脑实质病变的病人中，结果令人震惊，激素治疗的死亡或依赖的比值比增加 4.8 倍 (95% CI 1.2- 19.8)。

### 抗生素

局部 (如，中耳炎、中耳乳突炎) 和全身性 (脑膜炎，败血症) 感染可以合并附近或远隔静脉窦血栓形成。怀疑感染和 CVT 病人的处理应包括应用适当的抗生素和感染灶 (如，硬膜下积脓或副鼻窦化脓性积液) 的手术引流。

早期并发症(脑积水、颅内压增高和抽搐发作)的处理和预防

### 抽搐发作

抽搐发作见于 37% 的成年、48% 的儿童和 71% 的新生儿 CVT 病人<sup>[102,183]</sup>。尚无临床试验对抗癫痫治疗在 CVT 中应用的最佳时机或药物选择进行研究。是否对所有 CVT 病例都开始抗癫痫治疗或等到有抽搐发作才开始抗癫痫治疗仍有争议。因为抽搐发作可加重缺氧性脑损害，所以即使一次抽搐发作之后就应用抗癫痫治疗也是合理的<sup>[217]</sup>。在没有抽搐发作的情况下，预防性应用抗癫痫药物可能有害 (引起副作用的风险可能超过其治疗益处)<sup>[196,197,209]</sup>。

几项研究报告了 CVT 病人抽搐发作的发生率和特征。一项研究报道<sup>[218]</sup>，在 91 例病人中，32% 以抽搐发作就诊，2% 在住院期间出现抽搐发作，仅 9.5% 出现晚期抽搐发作，此外，抽搐发作并不是 1 年预后的预测指标。早期抽搐发作在有 CT/MRI 上脑实质病变的病人中发生的可能性高达 3.7 倍 (95% CI 1.4-9.4) 而在有感觉缺失的病人中的可能性增加 7.8 倍 (95% CI 0.8-74.8)。来自 ISCVT 的一项更近的报告<sup>[197]</sup>显示，624 例病人中的 245 例 (39%) 以抽搐发作就诊，而 43 例 (6.9%) 在诊断后 2 周内出现早期抽搐发作。除了就诊时抽搐发作，仅诊断时 CT/MRI 上有幕上脑实质病变 (见于 58%) 与早期抽搐发作的发生有关 (OR 3.1, 95% CI 1.6-9.6)。此外，在有幕上病变而起病时没有抽搐发作的病人中，应用抗癫痫药物可使 2 周内抽搐发作的风险降低 70%，尽管这并没有统计学上的显著性 (OR 0.3, 95% CI 0.04-2.6)。在这些结果的基础上，作者建议对表现为抽搐发作的有幕上病变的急性 CVT 病人使用抗癫痫药物<sup>[197]</sup>。

### 脑积水

上矢状窦和横窦是通过横跨静脉窦壁突入到蛛网膜下腔并引流到静脉系统的高度血管化结构的蛛网膜颗粒进行脑脊液 (CSF) 吸收的主要部位。在

CVT，蛛网膜颗粒的功能可能受到障碍，潜在地导致 CSF 吸收的衰竭和交通性脑积水 (6.6%)<sup>[14,198]</sup>。

梗阻性脑积水是 CVT 的一个少见的并发症，可由出血破入脑室系统所致。通常与累及大脑内静脉的血栓有关，还可以与丘脑出血有关。此综合征在新生儿已有很好的描述但可以发生在所有年龄组<sup>[201,205]</sup>。神经外科脑室造瘘术清除 CSF，或对顽固性病例采用脑室腹腔分流术，是必需的。与其他梗阻性脑积水情况相比，大脑处在静脉压增高情况下，脑组织灌注处在更危险状态。因此，密切监测和神经外科会诊是重要的，因为在脑室扩大不太严重的情况下可能需要进行手术干预。

### 颅内压增高

高达 40% 的 CVT 病人表现为单纯颅内压增高<sup>[183]</sup>。以弥漫性脑水肿为特征，有时在 CT 上看似裂隙状脑室。临床特征包括进行性头痛、视乳头水肿以及第 III 或第 VI 对颅神经麻痹。导致颅内压增高的主要原因是静脉流出受阻和因 CSF 吸收障碍而加剧的脑组织淤血。

尚无任何随机试验证实最佳治疗；然而，对颅内压增高的合理处理应是采用多种治疗方法相结合。首先，减轻静脉流出血栓性阻塞的措施，诸如抗凝和溶栓治疗，可缓解颅内压增高。其次，通过腰穿放 CSF 至末压达到正常可即刻减轻颅内压增高。不幸的是，腰穿需要临时中断抗凝治疗，有血栓扩大的危险。尽管缺乏随机临床试验，醋氨酰胺是治疗 CVT 所致颅内压增高的一种常用的治疗选择<sup>[139]</sup>。它在 CVT 病人的颅内压增高的急性处理中起到有限的作用。醋氨酰胺是一种碳酸酐酶抑制剂，是一种弱的利尿剂且能减少 CSF 的产生。尽管偶尔被使用，但是皮质激素类并没有效果<sup>[216]</sup>且能带来相关的对缺血脑组织有害的高血糖和高乳酸的危险。如果有持续的颅内压增高，可能需要多次腰穿。对顽固性颅内压增高的病例，可能需要做腰大池腹膜腔分流术<sup>[199]</sup>。因为视神经长期受压可以导致永久性失明，所以在病人有颅内压增高期间密切监测视野和视乳头水肿的严重程度至关重要。眼科会诊对这一情况有帮助。尽管很少需要，但是视神经开窗术是阻止进行性视力丧失的一个治疗方法。

现有关于去骨瓣减压术在 CVT 合并脑水肿、静脉性梗死、神经系统功能恶化或濒临脑疝中的治疗作用的证据有限<sup>[200,202,203]</sup>。阻止术后近期的抗凝治疗是开颅手术的一个缺点。

### 建议

#### 1. 怀疑有细菌性感染的 CVT 病人应接受合理

的抗生素治疗且应在适当时机接受 CVT 相关性感染灶的化脓性积液的引流手术 (I 类推荐; C 级证据)。

2. 对 CVT 合并颅内压增高的病人, 建议监测有无进行性视力丧失, 而这一情况一旦被观察到, 则应紧急治疗颅内压增高 (I 类推荐; C 级证据)。
3. 对有脑实质病变的 CVT 合并单次抽搐发作的病人, 建议早期开始规定好疗程的抗癫痫药物以预防进一步的抽搐发作 (I 类推荐; B 级证据)。
4. 对没有脑实质病变的 CVT 合并单次抽搐发作的病人, 勉强地建议早期开始规定好疗程的抗癫痫药物以预防进一步的抽搐发作 (IIa 类推荐; C 级证据)。
5. 在没有抽搐发作的情况下, 不建议对 CVT 病人常规应用抗癫痫药物 (III 类推荐; C 级证据)。
6. 对 CVT 病人, 无论是否存在 ICH, 采用按剂量调节的 UFH 或基于体重的充足抗凝剂量的 LMWH 开始抗凝治疗是合理的, 后续应用维生素 K 拮抗剂 (IIa 类推荐; B 级证据)。(为了解详细情况, 参见“CVT 的急性期处理和初始抗凝治疗: 初始抗凝治疗。”)
7. 为治疗和预防 CVT 病人的临床并发症, 将病人收住到卒中单元是合理的 (IIa 类推荐; C 级证据)。
8. 对 CVT 合并颅内压增高的病人, 开始醋酸酞胺治疗是合理的。如果有进行性视力丧失, 其它治疗 (腰穿、视神经减压术, 或脑脊液分流术) 可能是有效的 (IIa 类推荐; C 级证据)。
9. 如果在强化抗凝治疗下发生病情恶化, 则可以考虑血管内介入治疗 (IIb 类推荐; C 级证据)。
10. 对因可引起难治性颅内压增高的严重占位效应或颅内出血而出现神经系统症状和体征恶化的病人, 可以考虑去骨瓣减压术 (IIb 类推荐; C 级证据)。
11. 对 CVT 病人, 即使在 CT/MRI 上存在脑实质病变, 不推荐激素类药物, 除非因其它基础疾病所需 (III 类推荐; B 级证据)。

#### CVT 的长期处理和复发 用或不用抗凝治疗的复发风险

预防策略集中在对那些 CVT 或其它 VTE 复发高危 CVT 病人的预防上。有某些易栓状态或疾患 (如, 癌症) 的病人可被认为高危病人。还没有关于首次或复发 CVT 长期预防的随机临床试验。总体上, 任何类型复发性血栓形成的年复发风险大约是

6.5%<sup>[10,117]</sup>。

因为还没有关于成年 CVT 病人抗凝治疗的二级预防试验, 因此仅能用评估正在用或不用抗凝治疗的 CVT 或 VTE 复发风险的观察性研究来做预防策略的评价。在一组于 1978 年至 2001 年间 Mayo Clinic 治疗的 154 例病人队列中, 56 例初始接受肝素和华法林两种治疗, 12 例仅肝素治疗, 21 例仅华法林治疗<sup>[61]</sup>。77 例 (50%) 用华法林治疗平均 9 个月, 25 例为终身服用华法林<sup>[61]</sup>。在 36 个月随访 (464 个病人年) 期间, 有 20 例病人 (13%) 共 23 次 VTE 复发, 大多数发生在第 1 年内。10 例病人有 CVT 复发 (2.2/100 个病人年), 11 例有 DVT 或 PE (2.8/100 个病人年)。9 次复发事件发生在病人正在服用华法林期间。随访 8 年之后, 华法林对存活或无复发存活没有影响<sup>[61]</sup>。

一组比利时一家大学医院连续治疗的 54 例 CVT 病人队列中, 平均随访 2.5 年, 8 例 (14.8%) 有 VTE 复发 (7 例为 DVT 或 PE, 1 例为 CVT 和肠系膜静脉血栓) (4.5/100 病人年)。复发的平均时间是 2.5 个月 (范围从 2 周至 4 年)。这 8 例病人中仅 2 例在复发时正在服用抗凝药, 1 例的国际标准化比率 (INR) 为 1.6, 另 1 例 INR 为 2.1。6 例没有正在服用抗凝药的复发 VTE 病人中, 复发发生在先证事件后 2 周至 10 个月之间。有某种易栓疾患、有 DVT 病史及没有接受口服抗凝药容易复发<sup>[176]</sup>。

在 ISCVT 研究中, 平均随访 16 个月期间, 624 例 CVT 病人中有 14 例 (2.2%) 复发 CVT 和 27 例 (4.3%) 其它血栓事件 (16 例 DVT, 3 例 PE, 2 例缺血性卒中, 2 例短暂性脑缺血发作及 4 例急性肢体缺血)<sup>[10]</sup>。这 41 例有复发或其它血栓性事件的病人中有 17 例 (41.5%) 正在服用抗凝药, 但这些正在接受治疗剂量的抗凝者服用的抗凝药类型和数量未知<sup>[10]</sup>。也未报道是否长期给予抗凝和是否复发事件依抗凝药物的应用而有所不同。

CVT 后任何血栓事件 (CVT 或系统性) 总的复发危险大约为 6.5%。基于对本病最大规模的研究<sup>[10]</sup>, CVT 之后其它 VTE 表现的危险是 3.4%<sup>[209]</sup> 至 4.3%<sup>[10]</sup>。有严重易栓症的病人 VTE 危险增加。

#### CVT 和其它 VTE 事件的二级预防

DVT/PE 和 CVT 有一些相同之处。两者的慢性或一过性危险因素是相似的。在 ISCVT 病例队列中, CVT 或其它 VTE 复发的总发生率是 4.1/100 人年, 男性和红细胞增多/血小板增多是被发现的唯一独立的预测因子<sup>[219]</sup>。同一研究报告了血栓性复发事件的累积危险的稳定增加不受抗凝治疗时间的影响, 提示需要开展一个临床试验评价短期与长期抗凝治

疗的疗效和安全性<sup>[219]</sup>。鉴于 CVT 之后系统性 VTE 比复发性 CVT 更常见,因此有理由采纳 VTE 的指南预防新的 VTE 和复发性 CVT<sup>[219,220]</sup>。然而,应该对每一个体病人进行危险评估,然后考虑病人的危险水平和关于长期抗凝治疗、出血危险以及不用抗凝情况下血栓形成的危险的选择<sup>[220]</sup>。

#### 易栓症和长期处理的危险分层

易栓症可能是遗传性的或获得性的,基于在非常大的家族病例队列中观察到的血栓复发危险,遗传性易栓症被分层为轻度或重度<sup>[221]</sup>。在 VTE 病人中,未正在接受抗凝治疗情况下 VTE 的累积复发危险最大的易栓症是抗凝血酶和蛋白 C 和蛋白 S 缺乏症,2 年复发率 19%,5 年复发率 40%,10 年复发率 55%。纯合子凝血酶原 G20210A、纯合子因子 V Leiden、蛋白 C、蛋白 S 或抗凝血酶缺乏症、联合性易栓性缺陷以及抗磷脂抗体综合征被分类为重度。

抗磷脂抗体综合征是一种获得性易栓症,伴有特殊的实验室标准(狼疮抗凝物、抗心磷脂抗体及抗 $\beta 2$ 糖蛋白 I)和静脉性或动脉性血栓事件或流产病史<sup>[224]</sup>。尽管没有报道针对 CVT 复发率的前瞻性研究,但是与此疾患相关的复发性 VTE 危险增高符合严重易栓症的定义。当前对 VTE 病人的建议要求对有抗磷脂抗体综合征的病人无限期抗凝治疗(调整剂量的华法林 INR 2.0-3.0 或肝素)<sup>[220]</sup>。

#### 其它能确定 CVT 后复发性 CVT 或 VTE 危险的实验室测定

在 DVT 或 PE 病人中,越来越多的证据提示临床上可用 D-二聚体测定确定复发 VTE 的风险<sup>[224,229,230]</sup>。尽管 D-二聚体应用于长期抗凝治疗行 VTE 二级预防看似有前途,但是标准化的 D-二聚体测定法的缺乏可能限制其在临床上的适用性和可信性<sup>[232]</sup>。

#### 建议

1. 检测血栓前状态,包括蛋白 C、蛋白 S、抗凝血酶缺乏症、抗磷脂抗体综合征、凝血酶原 G20210A 基因突变以及因子 V Leiden,可有益于 CVT 病人的处理。蛋白 C、蛋白 S 和抗凝血酶缺乏的测定的指征通常在完成抗凝治疗后 2 至 4 周。急性期或服用华法林病人的检测结果的价值非常有限(IIa 类推荐; B 级证据)。
2. 对应激性 CVT(与某种一过性危险因素相关的)病人,维生素 K 拮抗剂可以持续 3 至 6 个月,INR 目标值 2.0-3.0(IIb 类推荐; C 级证据)。
3. 对非应激性 CVT 病人,维生素 K 拮抗剂可以持续 6 至 12 个月,INR 目标值 2.0-3.0(IIb 类

推荐; C 级证据)。

4. 对 CVT 后有复发 CVT、VTE 或首次 CVT 合并严重易栓症(即,纯合子凝血酶原 G20210A、纯合子因子 V Leiden、蛋白 C、蛋白 S 或抗凝血酶缺乏症、易栓症联合缺陷以及抗磷脂抗体综合征)的病人,可以考虑无限期抗凝治疗,INR 目标值 2.0-3.0(IIb 类推荐; C 级证据)。
5. 可以考虑与在血栓研究领域有经验的医师会诊协助检测血栓前状态和治疗 CVT 病人(IIb 类推荐; C 级证据)。

#### 晚期并发症(而非复发性 VTE)处理

##### 头痛

头痛是 CVT 病人随访期间的常见主诉,大约见于 50% 的病人<sup>[193,205]</sup>。一般情况下,头痛为原发性且与 CVT 无关。对有持续的或严重的头痛病人,应做适当的检查排除复发性 CVT。偶尔,MRV 可显示之前曾闭塞过的静脉窦有狭窄,但对其临床意义并不清楚。头痛在随访期间更常见于表现为有急性单纯颅内压增高的病人。对这些病人,如果头痛为持续性且 MRI 正常,则需要做腰穿排除颅内压增高。

##### 抽搐发作

CVT 后局灶性或全身性抽搐发作可以被分为早期或远期(诊断后 2 周以上发生的)抽搐发作<sup>[10,197]</sup>。基于病例系列研究,远期抽搐发作可累及 5% 至 32% 的病人。这些抽搐发作大多数发生在随访第一年内<sup>[175,218]</sup>。对有单次抽搐发作的 CVT 合并脑实质病变的病人,建议开始一个规定疗程的抗癫痫药物治疗。

##### 视力丧失

CVT 所致的严重视力丧失罕有发生(2%-4%)<sup>[55,193,235]</sup>。视乳头水肿可造成短暂视力障碍,如长期存在,则可出现视神经萎缩和失明。视力丧失通常是隐袭性的,伴随进行性视野缩小和相对的中心视力回避。视力缺失更常见于有视乳头水肿病人和表现为颅内压增高的病人。延误诊断与晚期视力缺失危险增加有关。有视乳头水肿或视力障碍主诉的病人应该做全面的神经眼科检查,包括视敏度和正规视野检查。

##### 硬脑膜动静脉瘘

海绵窦、横窦或上矢状窦血栓形成可诱发晚期硬脑膜动静脉瘘<sup>[236]</sup>。这两种疾病之间的关系颇为复杂,因为:(1)硬脑膜动静脉瘘可以是持续的硬脑膜窦闭塞伴静脉压增高的晚期并发症;(2)如果静脉窦有再通则瘘可以闭合和痊愈;(3)先存动静脉瘘可以

是 CVT 的潜在病因。因为没有进行长期血管造影检查的队列研究, 因此尚不清楚 CVT 之后硬脑膜动静脉瘘的确切发生率。在没有系统性血管造影随访的队列研究中, 硬脑膜动静脉瘘的发生率低 (1%-3%)<sup>[55,94,201,205,237]</sup>。脑血管造影可有助于确定硬脑膜动静脉瘘的存在。

### 建议

1. 对有 CVT 病史主诉为新的、持续的或严重的头痛病人, 应考虑对 CVT 复发和颅内压增高进行评估 (*I 类推荐; C 级证据*)。

### 特殊人群的 CVT

#### 妊娠期 CVT

妊娠诱发凝血系统的改变, 这些改变可持续到产褥期且可导致高凝状态从而增加患 CVT 的危险。据估计, 在西方国家妊娠期和产褥期 CVT 的发病率的变化范围在 1/2500 至 1/10000 次分娩之间, 而 OR 变化范围从 1.3 至 13<sup>[238-240]</sup>。CVT 危险最大的阶段是妊娠晚期和产后最初 4 周<sup>[240]</sup>。在妇女中高达 73% 的 CVT 发生在产褥期<sup>[241]</sup>。剖腹产似乎与经年龄、血管危险因素、感染的存在、医院类型及地点调整后的 CVT 危险增高有关 (OR 3.10, 95% CI 2.26-4.24)<sup>[35]</sup>。

维生素 K 拮抗剂, 包括华法林, 与致死性胚胎病和胎儿及新生儿出血有关, 因此通常被认为禁用于妊娠期。因此, 大多数妇女妊娠期和早期产褥期 CVT 的抗凝治疗为 LMWH<sup>[220]</sup>。

与 UFH 不同, LMWH 与致畸或胎儿出血危险的增加无关。美国胸科医师学院抗栓指南强调妊娠期和产褥期 DVT 和肺栓塞的预防和治疗, 建议 LMWH 优于 UFH<sup>[241a]</sup>。他们建议治疗应从妊娠期持续至产后至少 6 周 (总的疗程为期 6 个月)。尽管这些建议针对的是系统性静脉血栓, 出于若干原因将这些建议应用于 CVT 是符合逻辑的。首先, 在致畸和胎儿/新生儿/母亲出血性并发症方面的安全性应该是相似的; 其次, 这些建议与非妊娠相关性 CVT 的治疗是一致的。就像对非妊娠妇女一样, 溶栓疗法应留给在系统性抗凝治疗下仍有病情恶化的病人, 其在妊娠期的应用已有报道<sup>[243]</sup>。

#### 未来妊娠和复发

与健康个体相比, 有既往 VTE 的病人再次发生静脉血栓事件的危险增加<sup>[244,245]</sup>。同样, 有 VTE 病史的妇女在未来妊娠时似乎也有血栓事件 (即, DVT、PE) 危险的增加<sup>[57]</sup>。妊娠, 特别是产褥期, 是已知的 CVT 危险因素。现有证据显示, CVT 并不是再次妊娠的禁忌证。鉴于妊娠给有 CVT 史的

妇女带来的额外危险, 再次妊娠期和产后期预防性 LMWH 可能有益处。

### 建议

1. 对于妊娠期 CVT 妇女, 整个妊娠期应持续给予全抗凝剂量的 LMWH, 而产后至少 6 个月应持续给予 LMWH 或 INR 目标值为 2.0-3.0 的维生素 K 拮抗剂 (总的疗程为期 6 个月) (*I 类推荐; C 级证据*)。
2. 有理由劝告有 CVT 史的妇女再次妊娠并非禁忌。关于潜在原因的进一步检查和与血液科专家和 (或) 母婴医学专家会诊是合理的 (*IIa 类推荐; B 级证据*)。
3. 有理由采用全量 LMWH 而非 UFH 治疗妊娠期急性 CVT (*IIa 类推荐; C 级证据*)。
4. 对有 CVT 史的妇女, 可以建议在未未来妊娠期和产后期预防性应用 LMWH (*IIa 类推荐; C 级证据*)。

#### 儿童人群中的 CVT

儿童 CVT 的发病率是 0.67/100 000 儿童/年<sup>[91]</sup>。当排除新生儿时, 报告的发病率是 0.34/100 000 儿童/年<sup>[249]</sup>。新生儿表现为抽搐发作或昏睡, 而年长婴儿和儿童 (与成年人相似) 通常表现为抽搐发作、意识水平改变、进行性头痛伴视乳头水肿、孤立性颅内压增高或局灶性神经功能缺失。

#### 危险因素

儿童 CVT 的危险因素与年龄相关。新生儿占儿童 CVT 病人的 43%<sup>[91]</sup>。新生儿患病危险性增加的可能原因有几种。首先, 出生过程中婴儿头部受到明显的机械性力的作用而导致颅骨沿颅缝线塑形, 这将引起其下的硬脑膜静脉窦发生机械性变形和损伤以及血栓形成。新生儿也有血栓倾向增大<sup>[250]</sup>。首先, 循环性母亲的抗磷脂抗体经胎盘转运到胎儿, 这种情况可持续到新生儿期<sup>[251]</sup>。其次, 新生儿循环性抗凝血蛋白 (包括蛋白 C、蛋白 S 及抗凝血酶) 水平下降, 而相对于成年人的血球压积较高。此外, 随着正常体液丢失和出生后生活第一周内相对性新生儿脱水而发生血液浓缩。半数以上的新生儿 CVT 有多种危险因素<sup>[252]</sup>。母亲怀孕和分娩的并发症可增加新生儿 CVT 的危险。母亲先兆子痫/子痫是新生儿 CVT 的一个危险因素<sup>[253]</sup>。包括头颈部感染、脑膜炎、继发于喂食困难或胃肠炎的脱水及先天性心脏病在内的新生儿疾病也可引起 CVT<sup>[91]</sup>。

在年长儿童和青少年, 系统性红斑狼疮、肾病综合征、L-精氨酸酶治疗的白血病或淋巴瘤以及外

伤是 CVT 的病因<sup>[102,245]</sup>。缺铁性贫血是一个已确定的 CVT 危险因素<sup>[254]</sup>。血栓前疾患在新生儿和儿童 CVT 中占 33% 至 66% 且当有其他 CVT 危险因素时经常出现<sup>[102]</sup>。

### 放射学诊断

就像在成年人一样, 做出诊断需高度怀疑 CVT 和特异性静脉成像检查。这一点对新生儿尤其重要, 新生儿没有特异性的临床表现, 大多数病人仅为抽搐发作。儿童 CVT 的神经影像检查结果与成年人相似。在新生儿, 二维 TOF MRV 有几个缺点, 包括仰卧位时枕骨挤压上矢状窦后部处局部区域没有血流。这种情况见于 14% 的没有 CVT 的新生儿<sup>[255,256]</sup>。因此, 经常需要 CTV 明确是否存在 MRV 所提示的 CVT。在新生儿, 经凶门多普勒超声可通过显示闭塞性血栓所致的血流缺失而提示 CVT, 然而, 尤其是闭塞性血栓, 这种技术不是太可靠<sup>[257]</sup>。

脑实质病变在新生儿比在儿童更容易是出血性的<sup>[102]</sup>。新生儿颅内出血经常包括幕上硬膜下出血。有脑室内出血的足月新生儿的病因为 CVT 者占 34% 的病例, 经常伴有丘脑出血<sup>[205]</sup>。

### 预后

新生儿、年长婴儿和儿童 CVT 有显著的不良预后的发生率。对新生儿, 需要长期随访确定预后, 因为神经缺失症状仅会随着历时数年的脑发育成熟才会变得明显。在 CVT 新生儿中, 28%<sup>[258]</sup>-83%<sup>[102,245,253,259]</sup> 可观察到神经系统功能缺失。

一项研究显示长期随访中 18% 的儿童 CVT 有后遗视力障碍。其它研究报道儿童和成年人 CVT 的结果相似<sup>[237,235,262]</sup>。

### 儿童人群中 CVT 的处理

考虑新生儿和儿童 CVT 的血管内治疗受到不良预后发生率高的驱动。还没有对儿童 CVT 进行过随机临床试验。因此, 治疗实践主要是来自成年人研究结果的外推。

对儿童, 且越来越多地对新生儿, CVT 治疗的主流是抗凝治疗, 包括 LMWH、UFH 及华法林。个体和地区性医疗在儿童 CVT 且特别是在新生儿 CVT 方面的差异非常大。抽搐发作可在超过 50% 的儿童人群 CVT 中观察到<sup>[102]</sup>。鉴于癫痫性抽搐发作在儿童病人中发生率较高, 那么可以考虑对无意识或机械性通气的儿童行连续的脑电图监测。

### 主要证据

尽管没有随机化试验, 但是越来越多的来自病

例系列和大规模观察性研究的证据支持抗凝在儿童或新生儿 CVT 中的疗效<sup>[72,179,201,236,263]</sup>。近期发表的一项来自荷兰的病例系列研究了抗凝在 CVT、脑室出血或丘脑出血的新生儿中的应用<sup>[201]</sup>。10 例新生儿中, 1 例婴儿在治疗开始前死亡, 2 例在常规应用 LMWH 治疗之前出生, 其余 7 例新生儿接受 3 个月的 LMWH (dalteparin), 以抗 Xa 水平 0.5-1.0 U/mL 为目标值。治疗期间没有出血增加或新发出血。另一项纳入 42 例儿童 CVT 的研究报告, 即使在存在 ICH 情况下, 抗凝治疗也是安全的且能改善预后<sup>[187]</sup>。最后, 在一项基于方案的抗凝治疗的前瞻性单中心研究中, 共纳入 162 例儿童病人, 大约半数在诊断时接受抗凝治疗, 包括 35% 的新生儿和 71% 的儿童。出血性并发症罕见 (6%), 均为非致死性且大多数临床预后良好。未经抗凝治疗的病人中超过 1/4 的新生儿和超过 1/3 的儿童被观察到有 CVT 扩大<sup>[264]</sup>。进一步关于以诊断时脑出血分层的最佳抗凝剂量正通过国际儿童卒中研究而处在计划阶段<sup>[265,266]</sup>。

### 已发表的儿童卒中指南

在过去 5 年间, 3 套针对儿童 CVT 治疗的指南被发表<sup>[267-269]</sup>。所有这 3 个指南都建议对非新生儿期的儿童采用 LMWH、UFH 和 (或) 华法林治疗 3-6 个月, 即使在脑出血存在的情况下。

与之不同的是, 关于对新生儿 CVT 的抗凝治疗没有一致的建议。3 个已发表的指南中, 1 个没有提及新生儿 CVT<sup>[268]</sup>, 1 个建议急性期抗凝<sup>[269]</sup>, 另 1 个建议不进行急性期抗凝<sup>[251]</sup>。特别是, 美国胸科医师学院建议初始抗凝, 除非存在明显出血的情况下, 而提议在这种情况下进行病例监测 CVT 是否扩大, 如果发生扩大则开始抗凝治疗。建议抗凝治疗至少 6 周且不超过 3 个月。提议在 6 周时应该做静脉成像检查, 而如果见到完全再通, 则可以停用抗凝。AHA 指南对初始抗凝未做出推荐意见。对有血栓扩大或易栓症 (其在急性疾病期间不会总被诊断出来) 的新生儿抗凝被认为是合理的。不情愿用抗凝治疗新生儿 CVT 基于若干担忧。首先, 缺乏对新生儿安全性的研究资料; 其次, 担心会增加新生儿脑对出血的敏感性。在当前预后文献发表之前, 不治疗新生儿的另一个原因是新生儿 CVT 的预后良好而因此治疗是不必要的这一错觉。如之前章节所指出的那样, 这些假设已经部分地被在过去几年发表的研究所推翻。然而, 在缺乏临床试验证据的情况下, 医疗实践的变异是可理解的<sup>[251]</sup>。

### 建议

1. 对儿童 CVT 的支持性措施应包括适当补液、

控制癫痫性抽搐发作以及颅内压增高的治疗 (*I类推荐; C级证据*)。

2. 既然 CVT 儿童有因严重或长期颅内压增高而发生视力丧失的可能性, 那么应做视野和视敏度的定期评估并应采取适当措施控制颅内压增高和其并发症 (*I类推荐; C级证据*)。
3. 对所有儿童病人, 如果撤除初始抗凝, 建议在诊断后的第 1 周重复包括静脉成像在内的神经影像以监测早期血栓扩大或新的梗死或出血 (*I类推荐; C级证据*)。
4. 对超过出生后 28 天诊断的急性 CVT 儿童, 即使存在颅内出血, 用全剂量 LMWH 治疗是合理的 (*IIa类推荐; C级证据*)。
5. 对超过出生后 28 天诊断的急性 CVT 儿童, 继续 LMWH 或口服维生素 K 拮抗剂 3-6 个月是合理的 (*IIa类推荐; C级证据*)。
6. 对所有急性 CVT 儿童病人, 如果开始初始抗凝治疗, 治疗后在最初 1 周做头部 CT 或 MRI 以监测其它出血是合理的 (*IIa类推荐; C级证据*)。
7. CVT 儿童可从为识别潜在凝血缺陷而做的易栓症测定中获益, 一些易栓症可影响随后再血栓的危险性并影响治疗决策 (*IIb类推荐; B级证据*)。
8. CVT 儿童可从利用血培养和副鼻窦放射检查调查潜在感染中获益 (*IIb类推荐; B级证据*)。
9. 对急性 CVT 新生儿, 可以考虑用 LMWH 或 UFH 治疗 (*IIb类推荐; B级证据*)。
10. 鉴于在急性 CVT 儿童中癫痫性抽搐的发生率, 可以考虑对无意识或机械性通气的个体进行持续的脑电图监测 (*IIb类推荐; C级证据*)。
11. 对急性 CVT 新生儿, 可以考虑持续 LMWH 治疗 6 周至 3 个月 (*IIb类推荐; C级证据*)。
12. 血管内介入治疗在儿童病人中的用途和安全性不确定, 仅可考虑将其用于仔细选择的在强化或治疗水平抗凝治疗下有进行性神经系统功能恶化的病人 (*IIb类推荐; C级证据*)。

### 临床结局: 预后

关于 CVT 的结局和预后有几项研究和综述 [181,256,257]。这类研究大多数是回顾性的 (总的或部分) [14,63,66,90,136,175,179,190,194,233,270-274]。为数不多的前瞻性研究中, 一些研究并没有分析预后因素 [178,193,261] 或仅对这些预测因子做了双变量分析 [275,276] 或仅对特殊病人亚组做了分析 [42,84,89,192]。仅有 5 项队列研究分析 CVT 病人短期和长期结局的预测因子 [5,55,93,167,203]。

诊断后神经系统功能恶化

神经系统功能恶化可以发生在 23% 的病人, 甚至在诊断后数天。神经系统功能恶化以意识水平下降、精神状态紊乱、新的抽搐发作、局灶体征恶化或新的局灶体征、头痛强度增加或视力丧失。当重复神经影像检查时大约三分之一有神经系统功能恶化的病人会有新的脑实质病变。入院时有意识水平下降的病人更容易恶化 [1,278]。

早期死亡

大约 3%-15% 的病人死于本病的急性期 [28]。大多数早期死亡是 CVT 的结果。CVT 急性期死亡的主要原因是继发于大的出血性病变的经天幕脑疝 [5], 其次是多发病变或弥漫性脑水肿所致的脑疝。早期死亡的其它原因包括癫痫持续状态、内科并发症和 PE [136,279]。

晚期死亡

急性期后死亡主要与基础疾病有关, 特别是与恶性疾病有关 [10,14]。

长期结局

在 ISCVT 研究中 [55], 最后一次随访 (平均 16 个月) 时在 79% 的病人中观察到完全恢复; 然而, 随访结束时总的死亡率是 8.3%, 而生活不能自理率为 5.1% (mRS 评分  $\geq 3$ )。在一项包括回顾性和前瞻性研究的系统回顾中, 总的死亡率是 9.4%, 而生活不能自理 (mRS 评分  $\geq 3$  或 Glasgow 预后量表评分  $\geq 3$ ) 的比例是 9.7% [28]。7 项队列研究 (包括资料可被分别分析的回顾性/前瞻性研究的前瞻性部分) 中, 总的死亡和生活不能独立的发生率是 15% (95% CI 13%-18%) [10]。

神经心理和神经精神后遗症

关于 CVT 存活者长期神经心理和神经精神预后的资料很少 [260,272]。尽管大多数 CVT 病人有明显的全面良好恢复, 但是大约一半存活者感到抑郁或紧张, 而且轻微的智能或语言缺陷可妨碍重返工作 [260,272]。

意志力丧失、执行力缺失以及健忘可由深静脉系统血栓伴双侧丘脑广泛梗死所致。记忆缺失、行为问题或执行力缺陷可以持续存在 [263,280]。

失语, 通常为流利型, 可由左侧横窦血栓伴颞叶梗死或出血引起。通常恢复良好, 但轻度自发语言和命名障碍可以持续。

长期预后不良的危险因素

在 ISCVT 队列中长期预后不良的危险因素是中

中枢神经系统感染、任一恶性病、深部静脉系统血栓、入院时 CT/MRI 上颅内出血、格拉斯哥昏迷量表 (GCS) 评分 <9、精神状态紊乱、年龄大于 37 岁以及男性<sup>[55]</sup>。可导致早期死亡的脑疝更多见于年轻患者，而由于恶性病所致的晚期死亡和不良功能预后更常见于老年病人<sup>[6,10,89]</sup>。入院时 GCS 评分 14-15、完全或部分颅内压增高综合征 (包括孤立性头痛) 作为仅有的 CVT 表现以及没有失语是预后良好的相关指标<sup>[117,177]</sup>。

### 危险评分模型

尽管总体预后良好，但是大约 15% 的 CVT 病人死亡或因 CVT 变得不能自理<sup>[10,283]</sup>。危险分层评分可以提高我们告知 CVT 病人其个体预后和选择可从加强监护和有创性治疗强化中获益的能力。一项研究创建并验证了一个预测不良预后的危险评分模型。此危险评分模型的分值范围从 0 (最低危险) 至 9 分 (最高危险)，而界限 (cutoff) 值  $\geq 3$  提示 6 个月时的死亡或不能自理。存在恶性病、昏迷或深静脉系统血栓为 2 分，而男性、存在意识水平下降或 ICH 为 1 分。在验证样本中推导队列预测能力 (c 统计量) 为 85.4%、84.4% 和 90.1%。在合并样本中的敏感性和特异性分别是 96.1% 和 13.6%。

另一研究<sup>[284]</sup>将年龄大于 37 岁和中枢神经系统感染合并到此模型中，并给每一个指标指定一个加权指数。此研究验证了 90 例 CVT 病人的评分并得出了一个 0.81 的受试者工作特征曲线下面积预测死亡率。界限评分  $\geq 14$ ，敏感性是 88% 而特异性为 70%。良好预后 (被定义为 mRS 评分 <2) 的预示值为 95%，而不良预后的预示值为 30%。

### 血管再通

在一项包括五项小规模研究的系统回顾<sup>[28]</sup>中，CVT 血管再通率在随访 3 个月时和 1 年时分别为 84% 和 85%。观察到脑深部静脉和海绵窦血栓的再通率最高，而横窦血栓的再通率最低<sup>[193]</sup>。在成年人中，闭塞静脉窦的再通与 CVT 的预后无关<sup>[41,194]</sup>。

## 总结/进一步思考

本声明提供了一个对 CVT 的诊断和处理及其最常见并发症有关文献广泛的和评论性的综述。

硬脑膜窦或脑静脉血栓形成 (CVT) 占有卒中中的 0.5% - 1%，最常累及年轻人和育龄妇女<sup>[1,4,6]</sup>。CVT 病人通常表现为头痛，尽管一些病人有局灶性神经功能缺失、意识水平下降、抽搐发作或没有局灶性神经系统体征的颅内压增高<sup>[1,4,6]</sup>。少见情况下，隐袭性起病可以给诊断带来挑战。大约三分之二的静脉窦血栓病人有一种促凝血因子或一个直接的病因。通常靠 CT(CTV) 或 MRI(MRV) 静脉造影检查显示由血栓所致的静脉窦或脑静脉的阻塞做出诊断<sup>[70,96]</sup>。CVT 的处理包括对基础疾病的治疗、对症治疗、对颅内压增高、ICH 或静脉梗死的并发症的预防和治疗，特别是抗凝治疗。

卒中的诊断和治疗技术正处在不断演变之中。在对脑静脉窦血栓形成的病理生理的认识上已经取得了重要进展。然而，有前途的技术 (血管内操作、用于处理有占位效应或 ICH 的难治性颅内压增高的偏侧开颅术等) 在被广泛使用之前还需要经过严谨的评价。

尽管近年对 CVT 的研究取得了实质性的进展，但是大多数文献仍然是描述性的。CVT 写作组为强调需要进一步研究的领域 (如，更大规模随机临床试验以明确治疗性干预的益处) 做出了努力并提供了反映当前标准临床实践的建议。一项旨在比较抗凝治疗和血管内溶栓的益处的随机临床试验 (Thrombolysis Or Anticoagulation for Cerebral Venous Thrombosis, TO-ACT Trial) 正在进行之中。TO-ACT 的结果可能有助于改进 CVT 病人的急性期处理。

CVT 的处理面对的困境可能是复杂的。鉴于文献中没有强有力的证据指导其中一些具有挑战性的临床决策，因此处理这类病人的医疗专业人员可能需要相关亚专业医师的协助。本声明不太可能终结关于 CVT 处理的争议。更确切地讲，本声明的内容应被视作对当前现有最佳证据的汇集。通过一个创新的研究和系统性评价的过程，诊断、处理和治疗方法将不断演变并因此而给 CVT 病人带来更好的预后。